

Joint Mobilisation

By Dr. Joseph E. Muscolino DC.

The full role that a massage therapist can play in addressing deep intrinsic fascial joint ligaments and joint capsules is still not fully appreciated, writes US-based chiropractic physician and massage therapy educator Dr. Joseph Muscolino. He suggests adding joint mobilisations to your practice and says it is an extremely powerful and effective technique.



Dr. Joseph E. Muscolino has been a massage therapy educator for 25 years. He is author of The Muscle and Bone Palpation Manual, With

Trigger Points, Referral Patterns, and Stretching, and other textbooks. Joseph also teaches continuing professional education courses.

For more information, please visit his website at www.learnmuscles.com.

Orthopedic massage therapy

In recent years, the popularity and acceptance of massage has grown tremendously. Once considered a luxury or treat, massage is now understood to be an integral part of complementary alternative medicine. Indeed, many people turn to their massage therapist for clinical orthopedic massage to remedy their musculoskeletal conditions before consulting their chiropractic or medical physicians. Yet, if the average person is asked what orthopedic massage treats, the answer will likely be tight muscles. Although it is excellent that massage therapists are recognised as muscle therapists, it is unfortunate that the understanding of the scope of massage therapy is often limited to musculature. After all, massage therapy does not just treat tight muscles, it treats all taut soft tissues: muscles, their associated fascial tissues, and joint ligaments and capsules.

Fascia/intrinsic joint ligaments and capsules

The increased focus lately on myofascial meridians has brought muscular fascia to the forefront in many continuing education courses, as well as the curricula of many massage therapy schools. But the full role that a massage therapist can play in addressing deep intrinsic fascial joint ligaments and joint capsules is still not fully appreciated.

Broad stretching

One approach that a massage therapist can take toward loosening these taut joint tissues is stretching. When a body part is stretched at a joint, a stretching force is placed upon the soft tissues located on the “other side” of the joint, including deeper joint tissues. For example, if a body part is moved anteriorly into flexion, the stretching force is placed upon the posterior soft tissues that cross that joint. However, stretching is often of limited value because it is applied over a large area instead of being focused on specific tissues. This is true whether the

stretching technique employed is classic static stretching, dynamic stretching, or even advanced neural inhibition stretches such as proprioceptive neuromuscular facilitation (PNF) or agonist contract (AC) stretching*.

The possible ineffectiveness of a broad stretching force is especially apparent when stretches are applied to the spine. These stretches may be ineffective because taut spinal tissues are often deeper intrinsic muscles and ligaments, such as rotatores, multifidi, intertransversarii, and joint capsules and ligaments. And these taut intrinsic soft tissues are located at a specific segmental joint level, for example the C4-C5 joint, which results in decreased motion at that one joint (this is a type of joint dysfunction known as a hypomobility).

But if the neck is stretched in this example, the entire cervical spine will be stretched, diluting the stretching force across all the cervical spinal joints. Similarly, any stretch of the mid to upper back will be diluted across the entire thoracic spine; and any stretch of the low back will be diluted across the entire lumbosacral region. Diluting the stretch often makes it ineffective at stretching the taut intrinsic tissues at any one segmental joint level. This problem is compounded by the fact that a hypomobile segmental joint is often surrounded by hypermobile joints that increase their motion to compensate for the lost motion of the hypomobile segment. Now, when a broad stretch is applied to this region, not only is the stretch diluted, but the adjacent compensatory hypermobile segments absorb all of the stretch, allowing the hypomobile joint to remain taut.

Joint mobilisation stretching

Therefore, to adequately alleviate a segmental hypomobility, in other words to mobilise a joint, the stretching force must be focused and directed at that specific joint level. The only stretching technique that can accomplish this is known as joint mobilisation. Joint mobilisation of the spine is not often thought of as stretching, but in essence it is. More specifically, joint

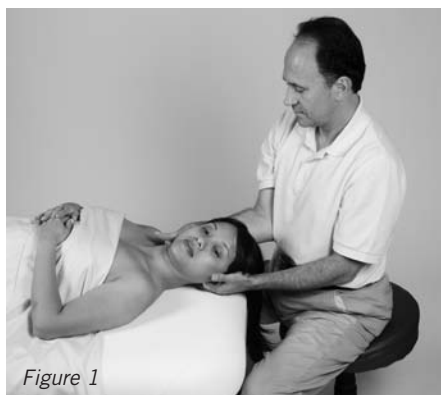


Figure 1

Joint mobilisation and joint manipulation

There is often confusion regarding the terms joint mobilisation and joint manipulation. Part of the confusion arises because different people and different entities and organisations define each of these terms differently. Technically and literally, a joint mobilisation is a type of joint manipulation. It is a joint manipulation in the sense that the joint is manipulated (moved by hand; the word root “manus” is Latin for hand). However, it is a low velocity joint manipulation that is performed in a slow and gentle manner, with no fast thrusting motion. A high velocity joint manipulation uses a fast thrust and is also referred to as an osseous adjustment or simply an adjustment. Osseous adjustments are performed by chiropractors and osteopaths. Regardless of how you define these terms, what is most important to realise is that joint mobilisations performed by massage therapists should never involve a fast thrust!

mobilisation can be considered to be a type of stretching technique known as pin and stretch. What sets joint mobilisation apart from pin and stretch, as well as all other stretching techniques, is the precision with which it is applied.

Joint mobilisation of the spine involves pinning (stabilising) one vertebra, and then introducing a stretch that causes the adjacent vertebra to move relative to the pinned one. For example, if the joint level being mobilised is C4-C5, the C5 vertebra is pinned and C4 vertebra is moved relative to it. This directs the stretching force to the intrinsic tissues of the C4-C5 joint that is located between them. By focusing the stretch to the specific joint hypomobility, adjacent compensatory hypermobilities are eliminated from the equation.

Because joint mobilisation technique is so powerful, the precision with which it is

applied is crucially important. Following are the steps that should be followed, using the C4-C5 joint as the hypomobile joint being mobilised. In this example, the joint is being mobilised into right lateral flexion (stretching the intrinsic soft tissues on the left side of the joint).

Starting position

The client is supine and the therapist is seated at the head of the table. For optimal body mechanics, the therapist is seated slightly toward the right side (Figure 1).

Support the head

The client’s head and neck are passively rotated to the left (approximately 30-45 degrees), and the client’s head is cradled and supported in the therapist’s left hand (see Figure 1).

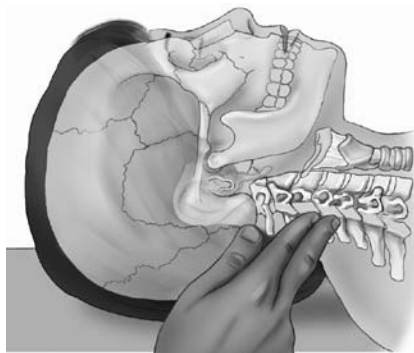


Figure 2

Place the pin contact

The therapist’s right hand contact is placed on the articular process (facet) of C5. This placement is extremely important. The articular process is located between the spinous and transverse processes, directly posterior to the laminar groove, and provides a broad flat surface for contact (Figure 2). It is extremely important that the client’s transverse processes are not contacted; they are pointy and would be very uncomfortable if pressure were to be placed upon them. There are three choices for the pin contact of the hand: the finger pads, the thumb pad, or the radial side of the proximal phalanx of the index finger (Figure 3a, b and c



Figure 3a



Figure 3b



Figure 3c

respectively). For the most part, choosing one contact instead of another is a matter of therapist and client comfort. Generally, the radial side of the index finger contact is the most powerful, but the finger pads are the most comfortable for the client.

Bring the joint to tension

The C4-C5 joint must now be brought to tension. This is achieved by the therapist using his/her left hand to right laterally flex the client’s head and upper cervical spine (the vertebrae superior to C5, i.e., C1-C4) until the end of passive range of motion is reached. While the client’s head is being moved, the therapist’s right hand pin contact must fully stabilise C5. If C5 is allowed to move at all, tension will be lost at the C4-C5 joint and the mobilisation will not be effective (Figure 4).



Figure 4

Mobilise the joint

Now that the joint has been brought to tension, the joint mobilisation force can be applied. This is done by gently increasing the motion at the joint beyond the tension point reached in the last step. This brings the joint past the end of passive range of motion into a range of motion that is known as joint play (Figure 5). This joint play motion can be performed in one of three ways:

The therapist's left hand can gently

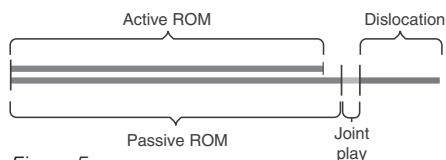


Figure 5

increase the amount of right lateral flexion of the client's head and upper neck around C5, while the right hand maintains the pin on C5.

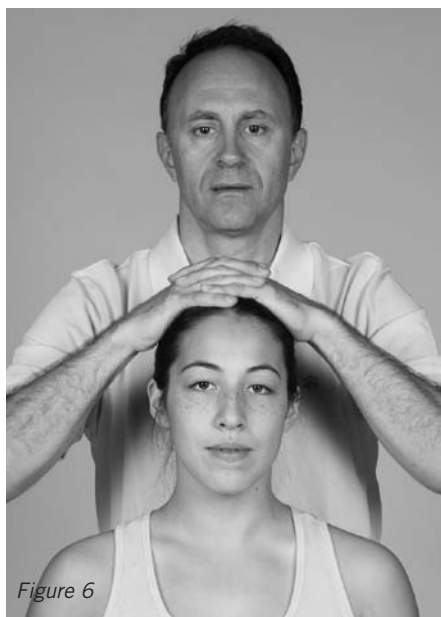

Figure 6

The therapist's right hand can gently push the articular process of C5 to the left "under" C4, while the left hand securely pins/stabilises the client's head and upper neck.

Both of the above can be done simultaneously. The therapist's right hand can gently push the articular process of C5 to the left while the left hand gently increases the right lateral flexion of the head and upper neck.

The mobilisation stretch should be applied for only one second or less, and it should not be painful or uncomfortable for the client. It is usual to repeat the mobilisation two to three times at that joint. Note: It is critically important to emphasise that a joint mobilisation force should never involve any type of fast thrust! If a fast thrust is done, then the therapist is performing an osseous adjustment joint manipulation that is within the scope of only chiropractors and osteopaths.

Mobilise the entire neck

Once the C4-C5 joint has been mobilised into right lateral flexion, the same procedure is repeated for the other joint levels of the neck. The same procedure can then be repeated for left lateral flexion. Once done, the entire process can be repeated for other ranges of motion of the neck.

Thoracolumbar spine and sacroiliac joints

In a similar manner, the entire thoracic spine, lumbar spine, and sacroiliac joints can also be mobilised. These regions require different positions for the client and therapist, but the principles of the procedure are the same.

Mobilise after the tissues are warmed up

As with any technique whose goal is to stretch taut soft tissues, joint mobilisation should always be done after the tissues are first warmed up. Warming the tissues can be accomplished by the application of moist heat (such as a hydrocollator pack) or by first massaging the area. For this reason, joint mobilisation is usually done toward the end of a treatment session.

Assessment

Before treatment is administered,

assessment should be done. Assessment is important for two reasons. It both informs the therapist about which tissues and structures need to be treated, and it informs the therapist about which treatment techniques can safely be performed.

Indications

The indication for joint mobilisation of the spine is the presence of a specific vertebral joint level that is hypomobile (or a few vertebral joint levels that are hypomobile). To determine this, joint play assessment needs to be done. Effectively, joint play assessment is performed identically to joint mobilisation technique. One vertebra is pinned, and the adjacent vertebra is moved relative to it until tension at the end of passive range of motion is reached. But now, instead of applying the joint mobilisation force for the purpose of mobilising the joint, a small force is applied for the purpose of assessing the ease of motion into joint play. This force is essentially a mobilisation force except that it may be even gentler than a typical mobilisation force. If the joint easily moves into joint play, theoretically, joint mobilisation is not needed at that vertebral level (although it could be administered proactively to maintain optimal motion just as massage or regular stretching could be administered to healthy tissues to maintain their health). If a restriction into joint play is found, joint mobilisation at that level is indicated.

Because the assessment procedure is the treatment procedure, some therapists like to combine assessment and treatment; if a hypomobility is found, it is immediately mobilised. Other therapists prefer to assess the entire spinal region, determine the hypomobilities, and then return and mobilise the indicated joint levels.

Contraindications

Contraindications for joint mobilisation are any space-occupying lesions that would cause spinal nerve or spinal cord pressure if the joint is moved into the range of motion needed to mobilise the joint. The most common space-occupying lesions are pathologic discs (bulging or herniated) and

the presence of large osteoarthritic (degenerative joint disease) bone spurs. If, for example, there is a bulging disc located posterolaterally on the right at the C4-C5 joint, mobilising the neck into right lateral flexion at that segmental level would be contraindicated (in fact, any right lateral flexion stretch would also be contraindicated in this case).

Assessment of a space-occupying lesion in carried out with foraminal compression test for the cervical spine (Figure 6), and passive straight leg raise for the lumbar spine (Figure 7).

Valsalva maneuver, in which the client

is asked to take in a deep breath, hold it in, and then bear down as if at stool in the bathroom, can be used for space-occupying lesions in both the cervical and lumbar regions. In all these assessment tests, a positive finding is found only if the client experiences sensory referral (such as pain or tingling) into an upper extremity for the cervical spine, or into a lower extremity for the lumbar spine. Assessment can also be made if the client has had an MRI of CT scan of the spine and given a diagnosis of a space-occupying lesion.

Adding joint mobilisations to your practice

If you practice clinical orthopedic massage, joint mobilisation should be added to your tool box of treatment techniques. It is an extremely powerful and effective technique. For clients who present with specific segmental spinal hypomobilities, it is the only treatment technique available to

massage therapists that can remedy their condition. However, because it is so powerful and requires such precision of application, it is best to learn joint mobilisation at hands-on workshops, and then thoroughly practice and hone it before performing on your clients. However, once learned, you will find that joint mobilisation is an invaluable addition to your practice; one that will increase not only your therapeutic success, but the success of your practice as well!

** PNF is also known as post-isometric relaxation (PIR) stretching or contract relax (CR) stretching. AC stretching is the basis for Aaron Mattes' active isolation stretching (AIS) technique.*

Credits: Figures 1, 4, and 6 reproduced by permission, Wolters Kluwer Health, Lippincott Williams & Wilkins from Muscolino JE: Forthcoming Advanced Treatment Techniques for the manual therapist: Neck, 2011.

Figures 2 and 5 reproduced by courtesy of Elsevier from Muscolino JE: The Muscle and Bone Palpation Manual, 2009 and Muscolino JE: Kinesiology: the skeletal system and muscle function, ed. 2.

Figure 3 reprinted by permission from the massage therapy journal photography by Yanik Chauvin.

Figure 7 photography by Yanik Chauvin.

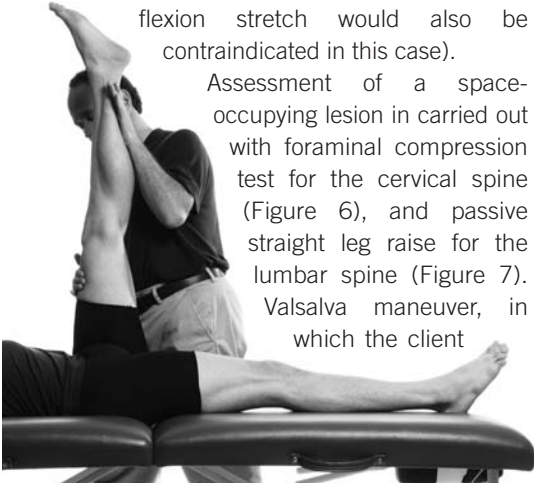

Figure 7