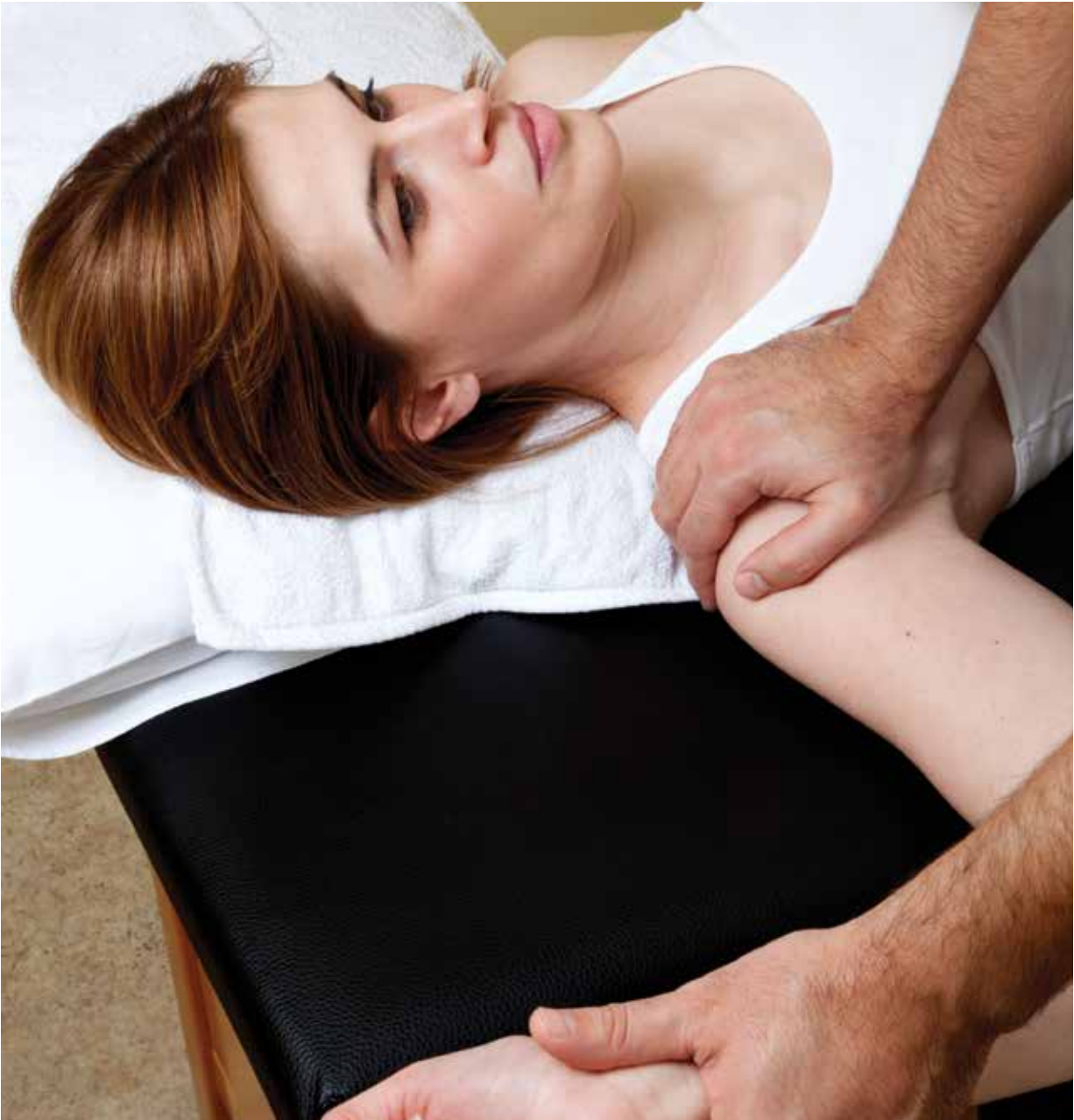


Body Mechanics

by Joseph E. Muscolino | Artwork Giovanni Rimasti | Photography Yanik Chauvin



Rotator Cuff Injury

WORKING WITH CLIENTS AFFECTED BY THIS COMMON CONDITION

ROTATOR CUFF GROUP

The four rotator cuff muscles are the supraspinatus, infraspinatus, teres minor, and subscapularis (Figure 1). These muscles are described

as the rotator *cuff* group because their distal tendons blend and attach together in a cuff-shape across the greater and lesser tubercles on the head of the humerus. Although all four rotator cuff muscles have specific concentric mover actions at the glenohumeral (GH) joint, their primary functional importance is to contract isometrically for GH joint stabilization. Because

Before practicing any new modality or technique, check with your state's or province's massage therapy regulatory authority to ensure that it is within the defined scope of practice for massage therapy.



the rotator cuff group has both mover and stabilization roles, it is extremely functionally active and therefore often physically stressed and injured. In fact, after neck and low back conditions, the shoulder is the most commonly injured joint of the human body.

ROTATOR CUFF PATHOLOGY

The three most common types of rotator cuff pathology are tendinitis, tendinosis, and tearing. Excessive physical stress placed on the rotator cuff tendon can cause irritation and inflammation of the tendon, in other words, *tendinitis*. If the physical stress is chronic, the inflammatory process often subsides and degeneration of the fascial tendinous tissue occurs; this is referred to as *tendinosis*. The degeneration of tendinosis results in weakness of the tendon's structure, and with continued physical stress, whether it is overuse microtrauma or a macrotrauma, a rotator cuff tendon *tear* might occur.

CAUSES

As stated, each of the four rotator cuff muscles has its own concentric GH joint action(s) for humeral motion: the supraspinatus abducts and flexes; the infraspinatus and teres minor laterally rotate; and the subscapularis medially rotates. However, as a group, the rotator cuff muscles are primarily important for isometric stabilization at the GH joint. Whenever the distal end of the humerus is moved upward, which occurs with flexion, extension, abduction, and adduction from anatomic position, the proximal end, the head of the humerus, must be stabilized down into the glenoid fossa of the scapula. The rotator cuff muscles are primarily responsible for this proximal stabilization. An example of this involving humeral abduction is shown in Figure 2. An isolated contraction of the deltoid to abduct the humerus actually results in a vertical pulling force upon the humerus and approximation of the humeral head against the acromion process above (Figure 2A). Downward stabilization of the humeral head by the rotator cuff musculature prevents approximation of the two bones when the deltoid contracts (Figure 2B). Therefore, between mover and stabilization functions, the rotator cuff musculature contracts with most every motion of the GH joint. It is this extremely heavy workload that commonly results in overuse and injury of the rotator cuff musculature.

REPETITIVE OVERUSE MICROTRAUMA

Injury of the rotator cuff group often takes the form of repetitive overuse microtrauma. This is especially true for people whose jobs involve continual use of the GH joint, such as house cleaners, assembly line workers, and carpenters. Athletes that heavily rely on upper ex-

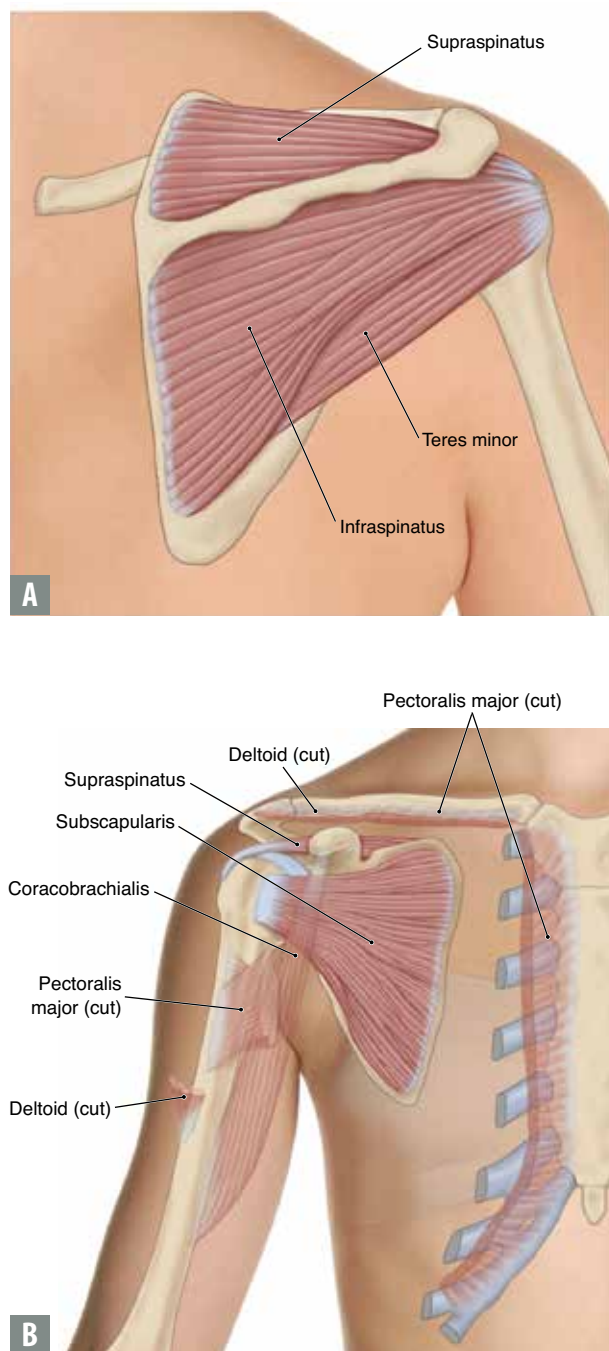


FIGURE 1. The rotator cuff group is composed of the supraspinatus, infraspinatus, teres minor, and subscapularis. A, Posterior view. B, Anterior view.

(Reproduced with permission from Joseph E. Muscolino. *The Muscular System Manual: The Skeletal Muscles of the Human Body*, 3ed. Elsevier, 2010.)

tremity motion, such as swimmers, tennis players, and baseball players, are also prone to repetitive overuse rotator cuff injury. These overuse patterns involve repeated microtrauma to the distal rotator cuff tendon that might result in tendinitis, or if extremely chronic, tendinosis or even tearing.

MACROTRAUMA

A macrotrauma is also a common cause of rotator cuff injury. Examples include a bad fall, lifting a very heavy object, or a motor vehicle accident. A macrotrauma can result in tendinitis; or if the trauma is severe enough, tearing. One of the most common causes of rotator cuff tearing occurs when a client who has an existing condition of rotator cuff tendinosis (and may not even be aware of it), experiences a macrotrauma. In these cases, even if the macrotrauma is only mild to moderately severe, because the tendon is already degenerated and weakened, tearing results.

THE CRITICAL ZONE

The entire rotator cuff group is often overused and injured. However, due to its location, the most commonly injured region of the rotator cuff distal tendon is the supraspinatus tendon. The distal tendon of the supraspinatus travels between the acromion process of the scapula and the head of the humerus. Whenever the arm is lifted into abduction, the supraspinatus tendon can become impinged between these two bony structures. Indeed, this region of the rotator cuff tendon is so often injured that it is often referred to as the *critical zone*. This is prevalent in clients who repeatedly or chronically have their arms raised to the side, such as barbers/hair stylists, artists, house painters, and people who sleep with their arm(s) above their head.

DYSFUNCTIONAL KINEMATICS

Impingement of the supraspinatus tendon between the head of the humerus and the acromion process of the scapula most often occurs with improper kinematics (motion patterns) of humeral abduction. There are three common dysfunctional kinematic patterns involving humeral abduction. One is humeral abduction coupled with humeral medial rotation; another is humeral abduction coupled with scapular downward rotation; and another is humeral abduction with decreased inferior glide of the humeral head.

COUPLED HUMERAL MEDIAL ROTATION

If the arm is medially rotated as it is abducted, the greater tubercle of the humerus becomes aligned in the frontal plane with the acromion process of the scapula. As a result, when the arm lifts into abduction, the great-

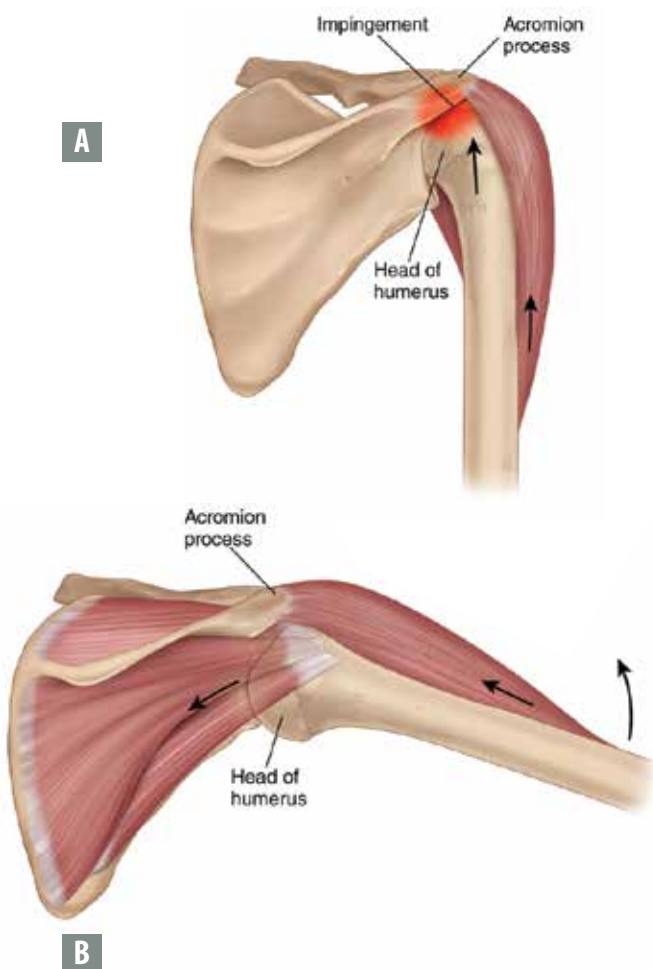


FIGURE 2. A, An isolated contraction of the deltoid results in approximation of the humeral head against the acromion process above. B, Downward stabilization of the humeral head by the rotator cuff musculature prevents this.

(Reproduced with permission from Joseph E. Muscolino.)

SHOULD WE ABDUCT THE ARM?

The question of why we would even want to abduct our arm to 90 degrees is a valid one. If we look at functional movement patterns in daily life, we see that abduction of the arm to 90 degrees is not that common or useful a motion. Indeed, pure abduction in the frontal plane to any height is not very functional. Try this: Stand looking straightforward and bring your arm into pure abduction in the frontal plane to 90 degrees. Can you even see your hand? The answer is no. So what purpose would it serve to move our hand to a position where we cannot even see what we are doing with it? We might choose to rotate our head and neck to see it, but we would just as likely, or more likely, rotate from lower in our body to accomplish this; and rotating our trunk toward the arm would effectively take the arm out of the position of pure frontal plane abduction relative to our body. Further, if we were to pick up an object with our arm out at 90 degrees of abduction, the leverage force that would result on our glenohumeral joint would be tremendous, resulting in great physical stress to the joint.

When examining movement of the arm out to the side, it is interesting to note that the hand first comes into view when it is moved forward approximately 30-35 degrees from the frontal plane. So let's now amend our previous exercise: As before, stand looking straightforward and bring your arm into pure abduction in the frontal plane; but now slowly bring your abducted arm anteriorly (horizontally flex) until you can see your hand. As stated, it will be approximately 30-35 degrees off the frontal plane toward the sagittal plane, which happens to be the plane of the scapula. It is unlikely that this is a coincidence. Movement of our arm out to the side is most functional when it is within the plane of the scapula, and therefore within our line of sight. The functional significance of movement of the arm within the plane of the scapula is so important that it is often referred to as scaption.

Looking at the larger picture of human motion, we see that the human body is primarily designed to move in the sagittal plane. It also moves well in the transverse plane to change our orientation. However, frontal plane motion is much more limited. Indeed, the elbow, knee, and ankle joints do not even move in the frontal plane. When it comes to the GH joint, it should be pointed out that pure frontal plane abduction to 90 degrees most often occurs during activities that do not involve motions of natural life, but rather motions involved in artificial, human-made activities, usually in the world of sports and the arts. Examples include ballet and tennis. Another example is working out in the gym, which often involves motions in the cardinal planes. It is ironic that gym workouts, which are supposedly designed to improve our health, might actually be injurious, at least when they involve pure frontal plane motions at the GH joint. The sagittal, frontal, and transverse cardinal planes are an excellent way to divide and map space when describing motions of the body. But there is no reason why our workout motions must be carried out within them. We should not become enslaved to moving only within the cardinal planes any more than we should insist on walking perfectly north and then perfectly west, when the easiest direction of motion to walk might be obliquely northwest!

er tubercle will eventually hit the acromion process, obstructing movement and pinching the soft tissues located between these two osseous structures. These soft tissues are the supraspinatus tendon and the subacromial bursa (Figure 3A). (Note: The superior aspect of the GH capsule, coracohumeral ligament, and long head of the biceps brachii tendon may also be impinged in this space.) Impingement of these tissues usually occurs at approximately 90 degrees of abduction. Lateral rotation, however, aligns the lesser tubercle with the acromion process in the frontal plane. Because the lesser tubercle is smaller than the greater tubercle, more room is afforded between the humerus and acromion and the soft tissues are less likely to be pinched (Figure 3B). For this reason, it is extremely important for the arm to be laterally rotated whenever it is abducted to approximately 90 degrees or more.

Unfortunately, many people have a difficult time laterally rotating their arms because they are stuck in humeral medial rotation. This can be due to fascial adhesions in the GH capsule, tight/overly facilitated medial rotator muscles (i.e., pectoralis minor, pectoralis major, subscapularis, latissimus dorsi, teres major), and/or weak/overly inhibited lateral rotator muscles (i.e., infraspinatus, teres minor, posterior deltoid). This muscular imbalance is often a result of a postural dysfunctional pattern known as *rounded shoulders*, which involves protracted shoulder girdles and medially rotated humeri. Rounded shoulders itself is usually part of the larger dysfunctional postural pattern of the body known as *upper crossed syndrome*.

COUPLED SCAPULAR DOWNWARD ROTATION

During humeral abduction, the scapula must be stabilized to prevent downward rotation. Otherwise, the critical zone of the supraspinatus tendon will become impinged. This is important because when the deltoid contracts to create abduction of the arm at the GH joint, it also pulls the scapula into downward rotation toward the humerus. This would cause impingement of the supraspinatus tendon and subacromial bursa between the head of the humerus and the acromion process; because as the humeral head is lifting upward toward the acromion process, the acromion process is moving downward toward the head of the humerus (Figure 3C). (It is worth noting that this impingement would occur even if the humerus were laterally rotated as it accompanies the humeral abduction.)

If instead, an upward rotator muscle (such as the upper trapezius, lower trapezius, or serratus anterior) contracts along with the deltoid, the scapula will be stabilized, preventing it from downwardly rotating, thereby preventing impingement of the tendon and bursa (Fig-

FIGURE 3.

Relationship between abduction of the humerus and impingement of the supraspinatus tendon and subacromial bursa.

A, Abducting a medially rotated humerus likely impinges the tendon and bursa.

B, If the humerus is laterally rotated as it abducts, impingement is less likely.

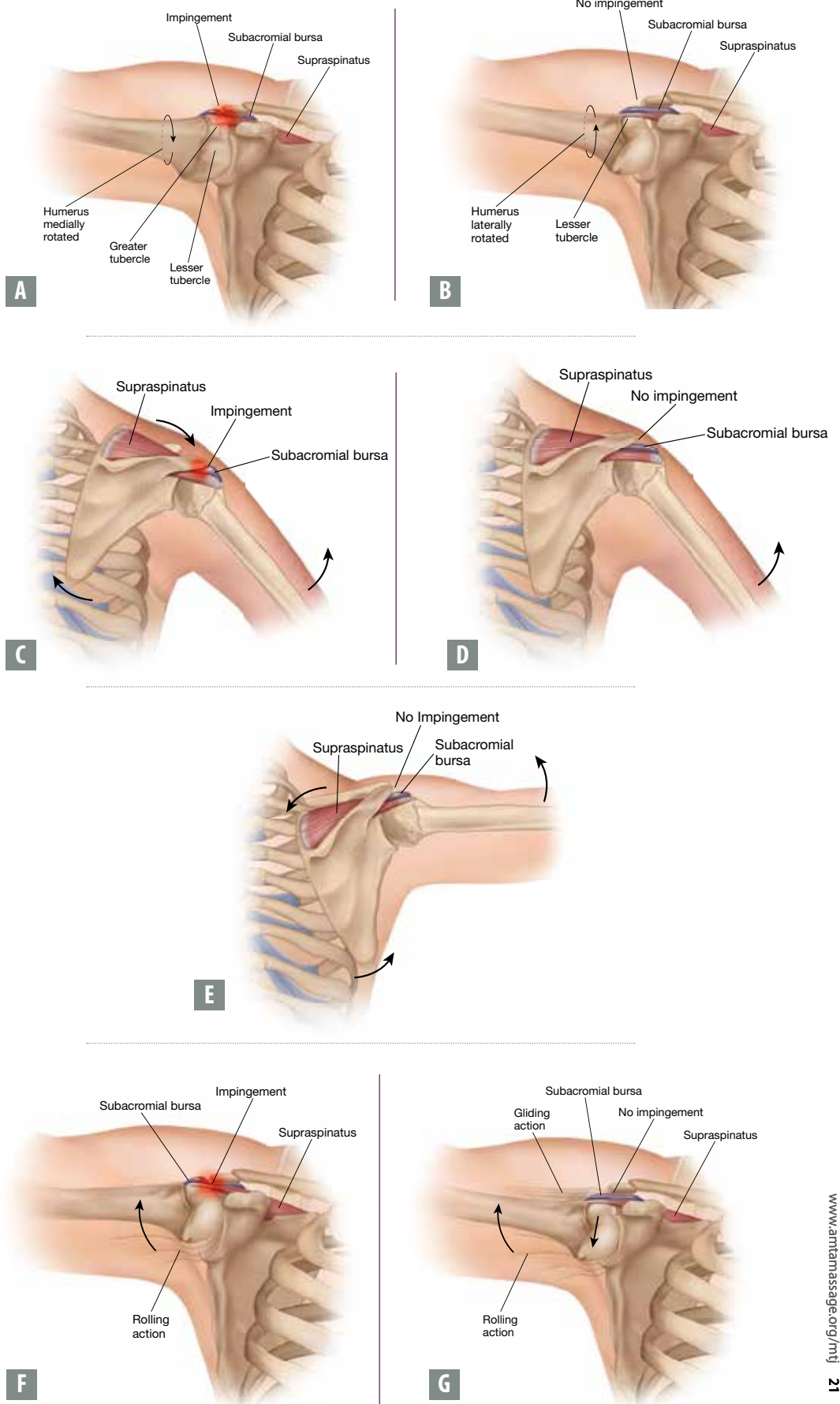
C, Abducting the humerus with scapular downward rotation may also cause impingement.

D, If the scapula is stabilized from downwardly rotating, impingement is less likely.

E, Coupling scapular upward rotation with further humeral abduction allows for greater motion without impingement.

F, Upward roll of the humeral head without compensatory inferior glide may also cause impingement.

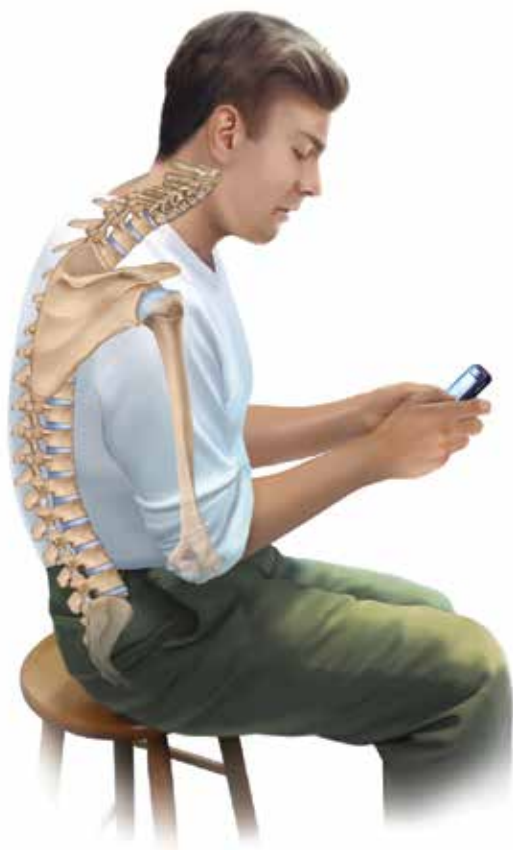G, Compensatory inferior glide decreases chance of impingement.



(Reproduced with permission from Joseph E. Muscolino.)

LATERALLY ROTATE WHEN ABDUCTING

The wisdom of coupling humeral lateral rotation with abduction is easy to experience. Slowly and carefully try the following: Medially rotate your arm as far as possible; then slowly begin abducting your medially rotated arm. How far can you abduct? To only approximately 90 degrees, right? Now laterally rotate your arm and then continue abducting. Can you feel the increased abduction that is now possible? This demonstrates the increased space allowed in the joint when the greater tubercle is moved out of the way of the acromion process.



UPPER CROSSED SYNDROME

Upper crossed syndrome is a dysfunctional postural pattern that predisposes clients toward having rotator cuff injury, as well as other conditions. Upper crossed syndrome involves protracted shoulder girdles, medially rotated humeri, hyperkyphosis (hyperflexion) of the thoracic spine, hypolordosis (hypo-extension or even flexion) of the lower cervical spine, hyperlordosis (hyperextension) of the upper cervical spine, and hyperextension and protraction of the head. Upper crossed syndrome often results from chronic postures such as use of a smart phone as seen in the accompanying figure.

(Reproduced with permission of Joseph E. Muscolino.)

ure 3D). It is important for this scapular stabilization to occur immediately at the outset of humeral abduction.

If humeral abduction continues beyond approximately 30 degrees, upward rotation musculature must contract to not only stabilize and stop the scapula from downwardly rotating, but to actually create scapular upward rotation motion. Upward rotation of the scapula allows further excursion of the arm into abduction without impingement (Figure 3E). Scapular upward rotation is so essential to abduction of the arm, that when an arm is fully abducted to 180 degrees, only 120 degrees of the motion is actually humeral abduction relative to the scapula; 60 degrees of the motion (fully 1/3) is due to scapular upward rotation!

Causes of insufficient scapular upward rotation force whether it is for stabilization and/or upward rotation motion include tight/overly facilitated scapular downward rotation musculature (pectoralis minor, levator scapulae, rhomboids) and/or weak or inhibited upward rotation musculature of the scapula. Insufficient scapular upward rotation can also be caused by fascial adhesions in the scapulocostal joint.

Note: Most scapular upward rotation motion is actually created at the sternoclavicular (SC) joint, located between the medial end of the clavicle and the manubrium of the sternum. Therefore, dysfunction of the SC joint can also be a cause of insufficient scapular upward rotation force and therefore dysfunctional humeral abduction. The acromioclavicular (AC) joint, located between the acromion process of the scapula and the distal end of the clavicle, is also involved with scapular upward rotation and can therefore be another source of insufficient scapular upward rotation and dysfunctional humeral abduction.

DECREASED INFERIOR GLIDE

Humeral abduction involves a superior (upward) roll of the head of the humerus relative to the glenoid fossa of the scapula. Pure upward roll would result in approximation of the head against the acromion process above, impinging the soft tissues located between them (Figure 3F). To prevent this, a compensatory inferior glide of the humeral head must accompany the upward roll. This inferior glide keeps the head from rolling upward into the acromion. This maintains centering of the bones in the joint (termed *centration*), thereby protecting the soft tissues located between them from impingement (Figure 3G). If there are fascial adhesions within the GH joint capsule/ligamentous complex that impede proper nonaxial inferior glide of the head of the humerus relative to the glenoid fossa of the scapula, the supraspinatus tendon and subacromial bursa can be injured.

OTHER FACTORS CAUSING IMPINGEMENT

There are other factors that can contribute to pathologic changes in the rotator cuff tendon.

Another possible cause of rotator cuff pathology is the shape of the acromion process of the scapula. Most often, the acromion process is either flat (termed *Type I*) or curved (parallel with the head of the humerus; *Type II*). However, the acromion can also be hooked (*Type III*) such that the distal end of the acromion hooks downward toward the head of the humerus. This shape is problematic because it increases the likelihood of impingement of the tendon/bursa between the acromion and humeral head. There is currently debate as to whether a hooked acromion process is genetic in origin or caused by chronic traction forces that are transmitted to the distal acromion from deltoid contraction; it is likely that both are true.

It is also common for bone spurs (osteophytes) to form on the underside of the acromion process. Similar to a hooked acromion, inferior acromial bone spurs narrow the space between the head of the humerus and acromion process, thereby increasing the chance of soft tissue impingement and injury.

SIGNS AND SYMPTOMS

The most common signs and symptoms of rotator cuff pathology are pain, joint crepitus (e.g., clicking or clunking noise), weakness, and/or decreased range of motion when moving the GH joint. Another common sign/symptom is hypertonicity, in other words global tightness of and/or trigger points (TrPs) in the rotator cuff muscle bellies. The degree of each of these signs and symptoms varies with the degree of the pathologic injury to the tendon. The location of the signs and symptoms varies based on which rotator cuff muscle's tendon is injured. Which range of motion is decreased also varies base on which rotator cuff tendon is injured.

The signs and symptoms of rotator cuff tendinitis, tendinosis, and a rotator cuff tear are similar; however, as a general rule, a tear will be accompanied by more joint crepitus than would tendinitis/tendinosis. When a tear is present, often a loud popping or clunking noise is heard and felt when the client attempts active movement. A complete tear that entirely ruptures the tendon of one of the rotator cuff muscles is usually the most severe injury and often results in a total or near total loss of the range of motion of that muscle.

ASSESSMENT

The primary methods of manual orthopedic assessment for a rotator cuff tendon injury are active contraction of its muscle belly, stretching of the muscle-tendon unit, and palpation. Remember, too, to be mindful of scope of

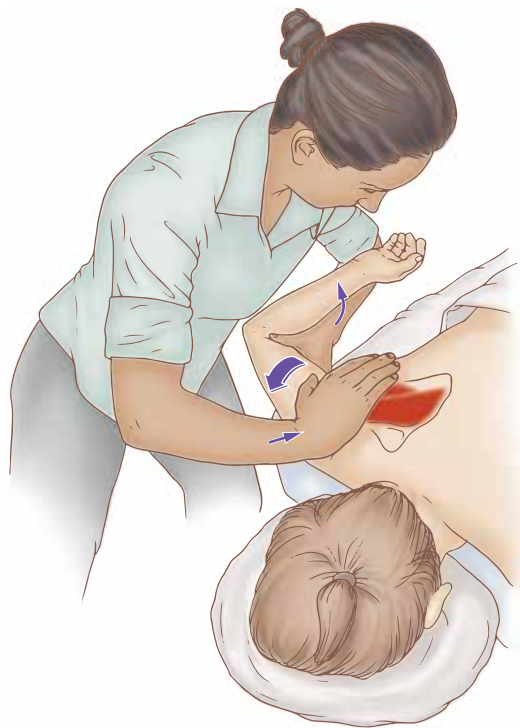


FIGURE 4. Length assessment of the teres minor and infraspinatus is performed by passively moving the client's arm into medial rotation.

(Reproduced with permission from Joseph E. Muscolino. *The Muscle and Bone Palpation Manual: With Trigger Points, Referral Patterns, and Stretching*, 2ed. Elsevier, 2016.)

practice during assessment.

Contraction of a rotator cuff muscle belly creates a pulling (tensile) force on its tendon; if the tendon is injured, this tensile force should elicit signs and symptoms, such as pain, crepitus, and/or weakness. Muscle contraction can be created by asking the client to perform active (concentric) range of motion (ROM) or by offering manual resistance to the motion, thereby causing the contraction to be isometric. For the rotator cuff, the principal ranges of motion to assess are abduction for the supraspinatus (or actually an oblique plane motion that is approximately 30-35 degrees off the frontal plane toward the sagittal plane, i.e., *scaption*), lateral rotation for the infraspinatus and teres minor, and medial rotation for the subscapularis.

Passive ROM stretching is effective for the assessment of tendon injury, especially tendinitis and/or tearing, because it places a stretching tensile force on the tendinous tissue. Stretching is also an effective assessment tool to identify hypertonicity in the rotator cuff musculature. If hypertonicity is present, passive motion in the opposite direction would be limited. For example, tightness in the teres minor and/or infraspinatus, lateral rotators, would result in decreased GH joint medial rotation (Figure 4).

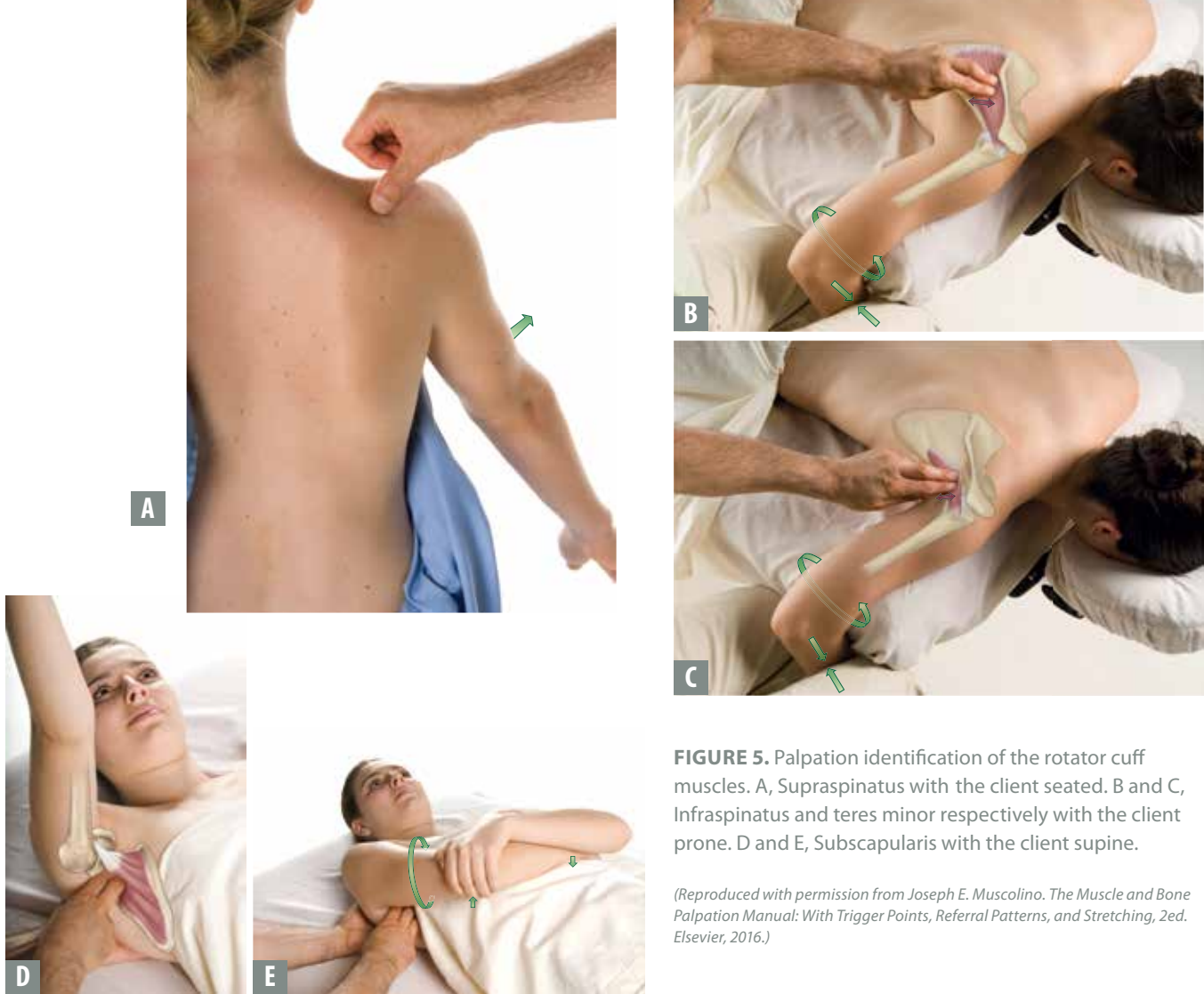

FIGURE 5. Palpation identification of the rotator cuff muscles. A, Supraspinatus with the client seated. B and C, Infraspinatus and teres minor respectively with the client prone. D and E, Subscapularis with the client supine.

(Reproduced with permission from Joseph E. Muscolino. *The Muscle and Bone Palpation Manual: With Trigger Points, Referral Patterns, and Stretching*, 2ed. Elsevier, 2016.)

Palpation is effective for the assessment of global muscle tightness and myofascial trigger points (TrPs), as well as inflammation of the tendons (Figure 5). Following is the protocol for palpation of the rotator cuff muscles. For the supraspinatus, palpate immediately superior to the spine of the scapula while the asking the client to move the arm approximately 30-35 degrees anterior to the frontal plane (Figure 5A). Unfortunately, most of the distal tendon of the supraspinatus is deep to the acromion process and not accessible to palpation. However, its actual humeral attachment can be felt deep to the deltoid immediately distal to the acromion process. For the infraspinatus and teres minor respectively, palpate lateral to the lateral border of the scapula while resisting the client from laterally rotating the arm (Figures 5B and 5C). For the subscapularis, reach in toward the anterior surface of the scapula while the client medially rotates the arm (Figure 5D). Inflammation would be palpated by the presence of heat and swelling. It is usually not possible to palpate and feel tendon degeneration.

MEDICAL DIAGNOSIS

Medically, a pathologic rotator cuff tendon is usually assessed by MRI study. MRI with contrast medium is especially effective for assessment of a rotator cuff tear. Tears are often described as a partial tear or a complete rupture, and the size of the tear is usually reported upon MRI. Ultrasound can also be used to diagnose rotator cuff pathology. An X-Ray is not an effective assessment procedure for an injured rotator cuff tendon because X-Rays only show bones, not soft tissues.

DIFFERENTIAL ASSESSMENT

There are a number of conditions that may to be differentially assessed when it is suspected that a client has an injured rotator cuff tendon. One is degenerative arthritic changes in the GH joint, which results in joint cartilage breakdown and the formation of bone spurs. Arthritic bone spur formation is easily identifiable on X-Ray. Two other conditions that may cause symptoms similar to rotator cuff pathology are a tear of the glenoid labrum and subacromial bursitis; these conditions

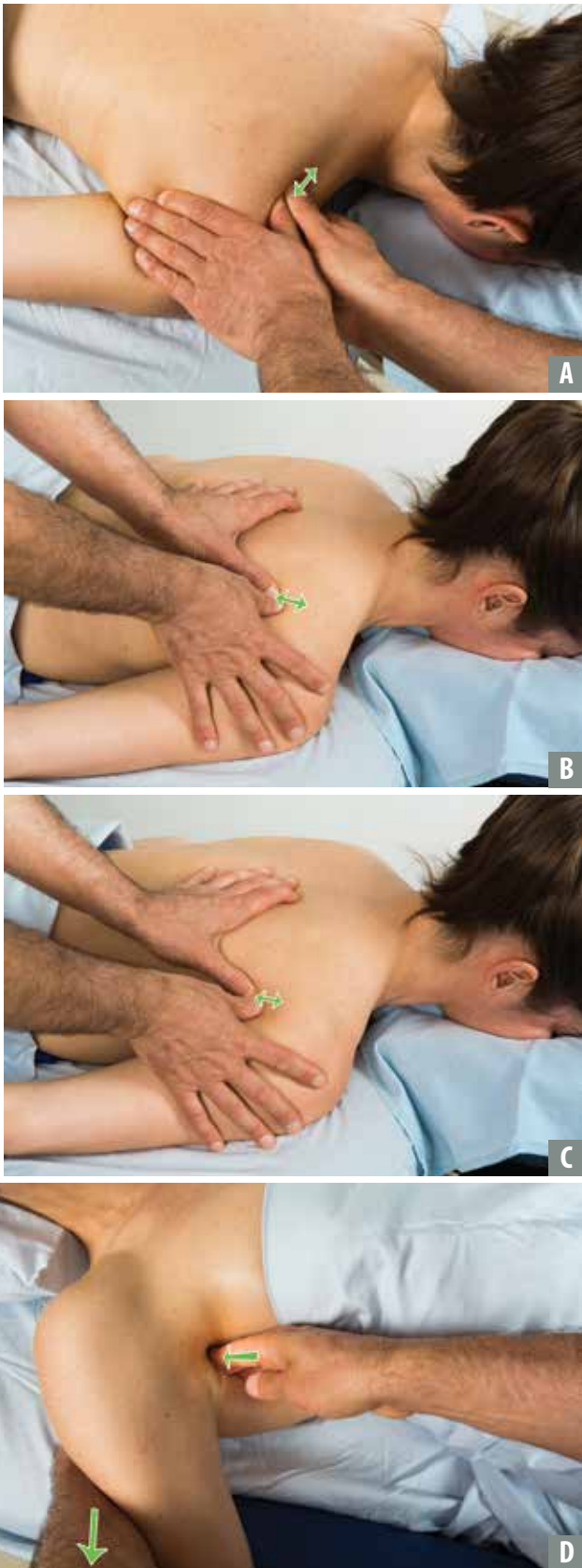

FIGURE 6. Soft tissue manipulation to rotator cuff musculature. A, Supraspinatus. B, Infraspinatus. C, Teres minor. D, Subscapularis.

are best assessed by MRI. It should be noted, however, that supraspinatus tendinitis and subacromial bursitis often occur together. These two structures are located together in the zone of impingement and they usually blend and attach into each other. Therefore, the presence of either one of these conditions usually accompanies (and indicates) the presence of the other.

One other condition that can mislead a therapist to believe that a client has an injured rotator cuff tendon is hypertonicity (global tightness and/or TrPs) in the rotator cuff musculature, or hypertonicity of other GH joint musculature (for example, the deltoid) because the pain pattern may be similar. Differentially assessing rotator cuff muscular hypertonicity from rotator cuff tendon pathology is especially challenging because hypertonicity of GH joint musculature usually accompanies rotator cuff injury. Therefore, if muscle hypertonicity is found, it is still necessary to assess for (in other words, rule in or rule out) rotator cuff tendon pathology.

MEDICAL APPROACH

Medical management of rotator cuff tendinitis usually involves prescription of oral steroidal anti-inflammatory medication such as cortisone, and/or cortisone injections. If tendinosis or tearing is present, prolotherapy injections, including platelet rich plasma (PRP) injections are usually very beneficial, and unless the tear is quite large, should certainly be considered and tried before opting for surgery. Indeed, PRP injections hold great hope for the treatment of not only rotator cuff injuries but for the treatment of all fascial degenerative tendinosis conditions and tears. For a PRP injection, the client's blood is drawn and spun down in a centrifuge to separate the components of the blood. The platelets and plasma are then injected back into the client in the region of the fascial injury. Platelets stimulate an inflammatory response that promotes healing of the injured tendon tissue. Because PRP injections utilize the client's own tissue, no artificial drugs/chemicals are used; hence the chance of unwanted side effects is lessened or entirely eliminated. But due to the fact that they create an inflammatory response, they can be temporarily uncomfortable for the client.

MASSAGE THERAPY

The type of massage therapy and its effectiveness for rotator cuff injury depends on the type of pathology present (i.e., tendinitis, tendinosis, tear), its severity, and the chronicity of the condition. As a rule, it is always wise to assess for and treat any and all hypertonicities found in the rotator cuff muscle bellies (Figure 6). Relaxing and loosening the muscular tissue does not directly heal the tendon pathology, but can diminish

the stress of excessive tensile muscle contraction force from being transmitted to the tendons.

Direct soft tissue manipulation work to the tendon can be beneficial toward breaking up possible adhesions; cross fiber strokes are usually most effective. If the client's pathology is tendinitis, then work done to the tendons should be mild to moderate in intensity so as to not appreciably increase tendon inflammation. Cryotherapy (icing) can be done after tendon soft tissue manipulation to decrease any possible swelling that results from the work.

If the tendon pathology is tendinosis or mild tearing, then deeper work across the tendons is indicated (Figure 7) and proactive communications with your client throughout the session are essential. Finger or thumb pads are usually the best contacts to access and work the area; tools may also be utilized. Sometimes this work can be extremely aggressive and uncomfortable for the client because the goal is to stimulate an inflammatory response (as with PRP injections), drawing in fibroblasts to mend the degenerated or torn fascial tissue. For this reason, bruising often occurs with this type of work. Whenever soft tissue work is done, even if it is strong in pressure, it is best to begin with light pressure, and then transition toward deeper pressure. When working on rotator cuff tendinosis and/or tearing, cryotherapy is contraindicated because it would lessen the desired inflammatory response and fibroblast healing that is being created by the manual treatment.

It should be pointed out that the pathologic state of a rotator cuff injury does not magically change from acute tendinitis to chronic tendinosis like a switch being flipped. Rather, there is a transition period of likely weeks, months, or longer, in which there is low grade swelling of the tendon *along with* degeneration of the tendinous tissue. In other words, tendinitis and tendinosis might exist together. In these cases, it is a judgment call for the therapist to choose which approach would be most effective for the client.

Regardless of the type of pathologic condition, the most difficult aspect of the rotator cuff tendon to address with massage therapy is the *critical zone* supraspinatus portion because most of it is located deep to the acromion process of the scapula and therefore inaccessible to manual treatment. Toward that end, passive stretching of the supraspinatus by adducting and extending the arm at the GH joint can help to slightly increase the amount of the supraspinatus distal tendon that is accessible to massage therapy (Figure 8).

Once direct care to the rotator cuff musculature has

been done, it is wise to work the surrounding region from the mid thoracic spine to the distal end of the upper extremity. Because injury to one side often results in overuse compensation by the other side, it is also beneficial to work the musculature of the opposite side shoulder. And because rotator cuff pathology usually results in decreased use of the shoulder, it is likely that adhesions will form in the capsule of the GH joint. Therefore, mobilization of the GH joint is usually beneficial and necessary. This is especially true if adhesions are limiting inferior glide of the head of the humerus.*

It should be noted that although massage therapy can be very effective for many rotator cuff injuries, larger rotator cuff tears will likely require more aggressive treatment, such as PRP injections or perhaps surgery.

PRECAUTIONS/CONTRAINDICATIONS

When working the rotator cuff musculature, aside from always working within the tolerance and comfort of the client, it is important to be aware that the radial nerve is superficial between the teres minor and teres major muscles. Also, if the client has a moderate or marked tear, stretching should either be performed with caution or avoided entirely. Assertive/aggressive stretching could increase the size of the tear.

SELF-CARE FOR THE CLIENT

Appropriate self-care for the client with rotator cuff pathology depends on the specific musculature that is affected and the specific pathology that is present. For any type of rotator cuff pathology, the client should avoid any offending postures and activities. Given the prevalence of the use of digital devices in our world, proper postures at the computer and with smart phones and tablets are particularly important. When using a desktop computer, the keyboard and mouse should be close to the edge of the desk so the client does not have to isometrically contract shoulder musculature to hold the arms out in the air to reach them. With a smart phone or tablet, it is also important to hold the device close to the body. Sleep posture is also extremely important. When sleeping, it is best to lie on the non-affected side and rest the injured-side arm on a large pillow in front of the trunk.

Foam rolling or rolling on balls should be recommended to reduce muscular hypertonicity and myofascial adhesions (Figure 9). Stretching may similarly help for clients with rotator cuff tendinitis and tendinosis conditions, but should be performed with caution or avoided if the client has a large tear. For tendinitis, icing should be recommended; but for tendinosis, it should be avoided. Clients

Note: Before practicing any new modality or technique, check with your state's or province's massage therapy regulatory authority to ensure that it is within the defined scope of practice for massage therapy.

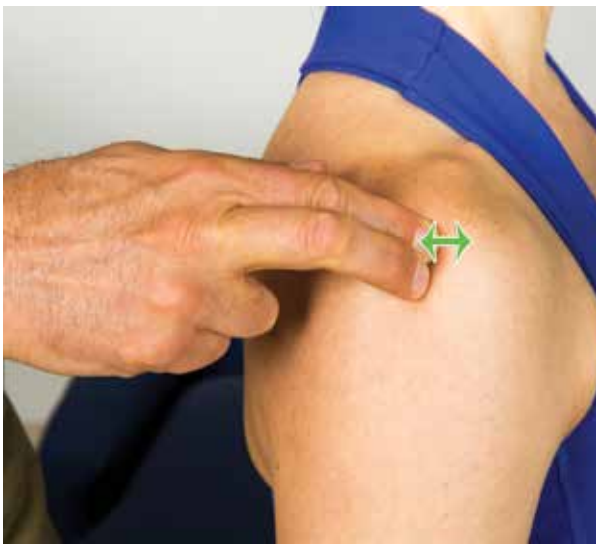

FIGURE 7. Cross fiber work to the supraspinatus tendon.

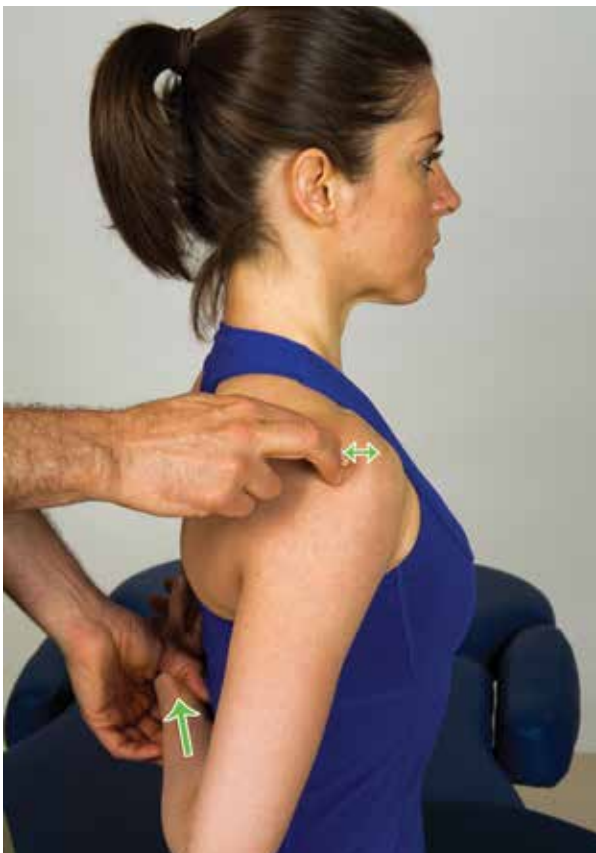

FIGURE 8. Adducting and extending the arm can allow slightly greater access to the distal tendon of the supraspinatus.



FIGURE 9. Self-care rolling manipulation of the infraspinatus.

(Photo courtesy of Jill Miller and Victory Belt Publishing. *The Roll Model - A Step-by Step Guide to Erase Pain, Improve Mobility and Live Better in Your Body.* [www.yogatuneup.com])

may also choose to take over-the-counter anti-inflammatory medication. If and when the condition has stabilized and signs and symptoms of the condition have lessened or resolved, strengthening the shoulder and upper trunk musculature should be recommended to help further improve the condition and to prevent future exacerbations.

SUMMARY

Massage therapy can be an incredibly important aspect of the treatment strategy for myofascial conditions, including rotator cuff injury. Given how often rotator cuff injuries occur, the massage therapist who practices clinical orthopedic work should be comfortable and familiar with the underlying mechanisms of rotator cuff tendinitis, tendinosis, and tearing, so that appropriate and effective assessment and treatment techniques can be carried out. ■

*For more on joint mobilization, see *body mechanics* article *The Importance of Joint Mobilization*, mtj, Summer, 2014 issue.



Joseph E. Muscolino, DC, is a chiropractor in private practice in Stamford, CT who employs extensive soft tissue manipulation in his practice. He has been a massage educator for more than 25 years and currently teaches anatomy and physiology at Purchase College, SUNY. He is the author of multiple textbooks including *The Muscle and Bone Palpation Manual*, *The Muscular System Manual*, and *Kinesiology* (Elsevier) and *Advanced Treatment Techniques for the Manual Therapist: Neck and Manual Therapy for the Low Back and Pelvis—A Clinical Orthopedic Approach* (LWW) and the author of multiple DVDs on *Manual Therapy*. Joseph teaches Continuing Education Clinical Orthopedic Manual Therapy (COMT) Certification workshops around the country and overseas. Visit Joseph's website at www.learnmuscles.com or his professional facebook page: *The Art and Science of Kinesiology*.