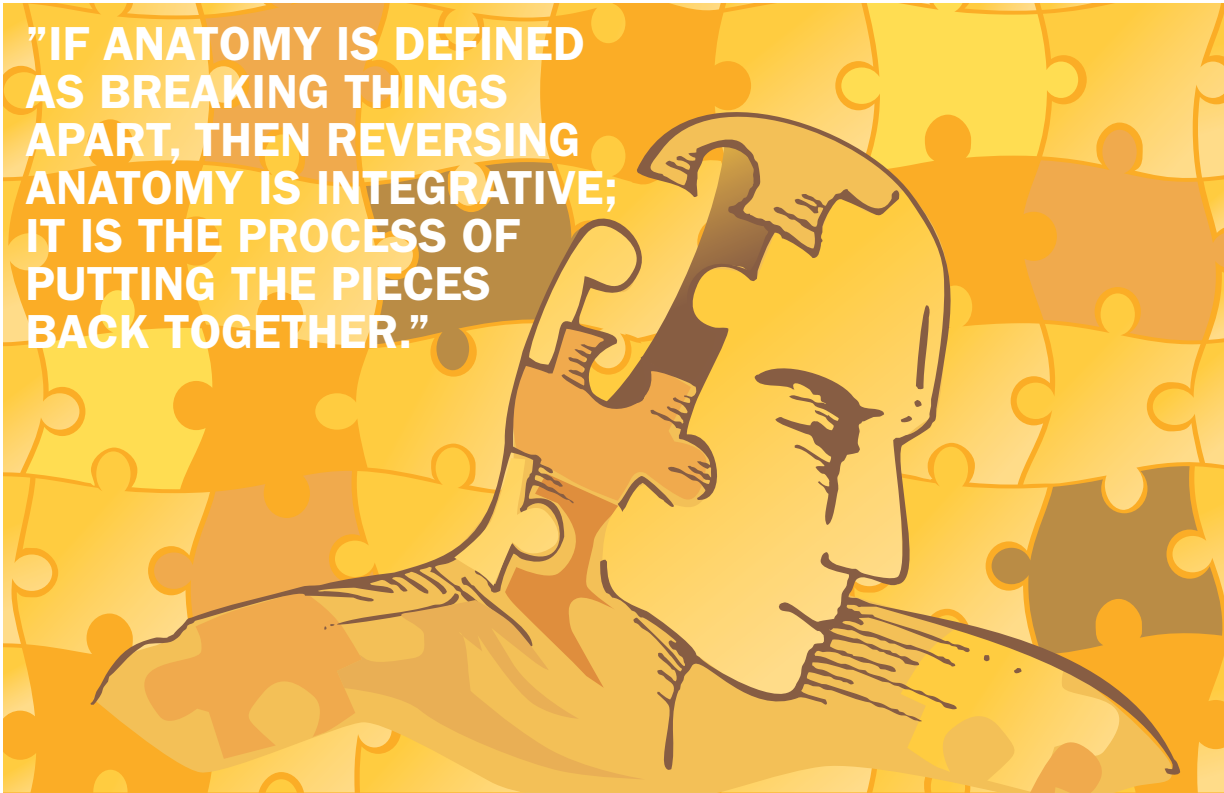

**"IF ANATOMY IS DEFINED AS BREAKING THINGS APART, THEN REVERSING ANATOMY IS INTEGRATIVE; IT IS THE PROCESS OF PUTTING THE PIECES BACK TOGETHER."**



## **reversing anatomy: from muscles to myofascial meridians**

As massage therapy continues to carve out its rightful niche in the world of integrative health, the responsibility to better know anatomy and physiology increases. Successful clinical orthopedic work cannot be accomplished with the application of memorized treatment technique routines. Rather, it requires critical thinking that is only possible with a true understanding of the principles of anatomy and physiology of the human body. Understanding these principles enables us to apply them to the specific circumstances of the client who is on the table, allowing for competent assessment and treatment.

### **ANATOMY AND PHYSIOLOGY**

Anatomy is the study of the structure of the body, and physiology is the study of the body's functioning. These are not the same things, but they are certainly related. It's the anatomic structure that determines the physiologic functioning of the body. Two musculoskeletal examples: 1) It is the rigid structure of a bone allows it to function as a lever, and 2) It is the presence of parallel actin and myosin filaments with cross-bridges between them in muscle tissue that allows for the sliding of one filament along the other, creating the functional pulling

force of muscle. Given that function follows from structure, structural anatomy is usually studied first so that physiologic functioning can then be understood.

### **THE CUTTING UP OF ANATOMY**

However, learning anatomy is usually a daunting task for students and therapists because it's basically a naming game, with thousands—if not tens of thousands—of names to learn. We cut the body up into smaller and smaller pieces, which are each named, usually with Latin root words. In fact, the term anatomy itself comes from the Latin-based roots *tome* and *ana*, which literally mean *cut up*. This is appropriate because it perfectly describes the origins of anatomy training, where a cadaver was cut up into pieces and the pieces were named.

This method of anatomy training still exists today, and for all its faults, is likely necessary. After all, it's impossible to present the entire human body to a student or therapist, and simply say "Here it is. Know it." To make this study feasible, we need to divide the body into smaller chunks of content so that they are more easily learned by the student.

The inherent risk involved with our approach to anatomy is that the more we divide up the body, the

more likely we are to lose sight of the bigger picture, where individual structures are interwoven to function together. In a sense, we risk ending up with thousands of jigsaw puzzle pieces, each one learned and committed to memory, without a good understanding of the picture they form.

This is certainly true when learning the muscular system. Learning muscles usually involves just that: learning each individual muscle one at a time, separate from the others. If our instructor and textbook do not present the bigger picture of muscular structure within the body, however, we will have learned the names of many pretty jigsaw pieces without having learned how they fit together. True understanding of kinesiology (human motion) requires more than memorizing lists of individual muscles; it requires a level of understanding that can only come from seeing the bigger picture of muscle structure and function. From this understanding, the application to competent clinical orthopedic work follows.

### STRUCTURAL AND FUNCTIONAL MUSCLE GROUPS

The solution involves proper framing of the content.

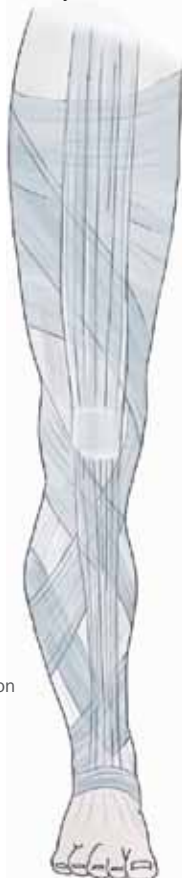Taking a step back and presenting a somewhat larger picture of musculature before studying the minutiae of individual muscles can be helpful.

Muscles can be organized into structural groups at a joint: these groups are located anteriorly, posteriorly, laterally, etc. When examining these structural groups, we can also relate them to their functions. For example, all muscles that cross the glenohumeral joint anteriorly with a vertical component to their fiber direction can flex the arm at the glenohumeral joint. Therefore, the structural group of anterior muscles (with a vertical orientation) is the functional group of flexors. Similarly, all posterior muscles oriented in this manner can extend the arm at the glenohumeral joint.

This reasoning can also be used for laterally oriented abductors and medially oriented adductors. Regarding rotations, all muscles that wrap horizontally around the glenohumeral joint on the anterior side can medially rotate the arm at the glenohumeral joint, and muscles that wrap horizontally on the posterior side can laterally rotate the arm at the glenohumeral joint.

Pointing out these structural groups not only facili-

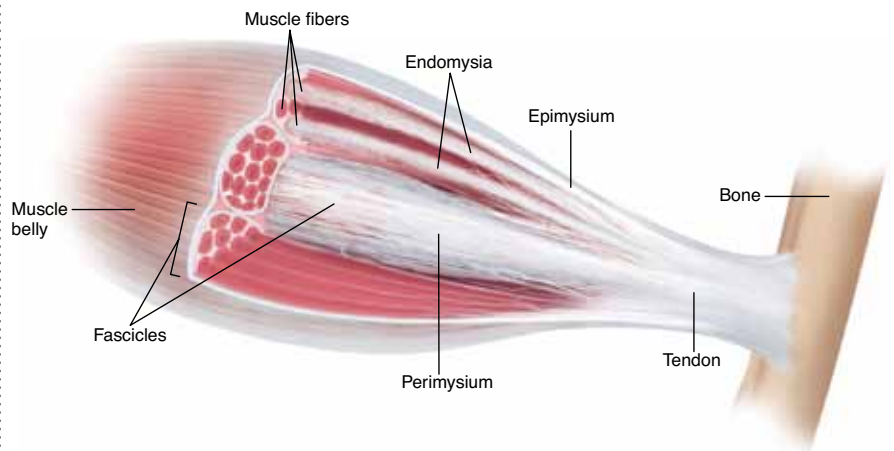
**Figure 1.** Fibrous fascia forms one continuous web that traverses and connects the entire body.



CREDIT: Paoletti, S: *The Fasciae: Anatomy, Dysfunction and Treatment*, Seattle, 2006, Eastland Press

**Figure 2.** The tendon (or aponeurosis) of a muscle is actually the coalescing of all the endomysia, perimysia, and the epimysium.

CREDIT : Illustrated by Giovanni Rimasti



tates our anatomic approach of learning the individual muscles by giving us a framework for their organization, it also immediately points out the anatomic/physiologic relationship between structural groups and functional groups, making critical and creative thinking possible.

### “REVERSING ANATOMY”

With the big picture of functional groups at each individual joint presented first, we can now learn each individual muscle. When that’s done, the next critical step is reversing anatomy.

If anatomy is defined as breaking things apart, then reversing anatomy is integrative—the process of putting the pieces back together. Now is the time to reassemble all the muscles that have been learned back into the big picture of the entire muscular system. This process is especially instructive now that we know and appreciate each individual jigsaw piece.

It’s now possible to see the larger picture of all the functional groups of mover muscles throughout the body, as well as the interrelationship between the functional groups, such as whether they are mover/antagonist pairs or mover/stabilizer pairs, for example. This level of knowledge is truly important when looking to understand and assess postural and movement patterns in the human body.

### FASCIAL WEBBING

However, the process of reversing anatomy does not

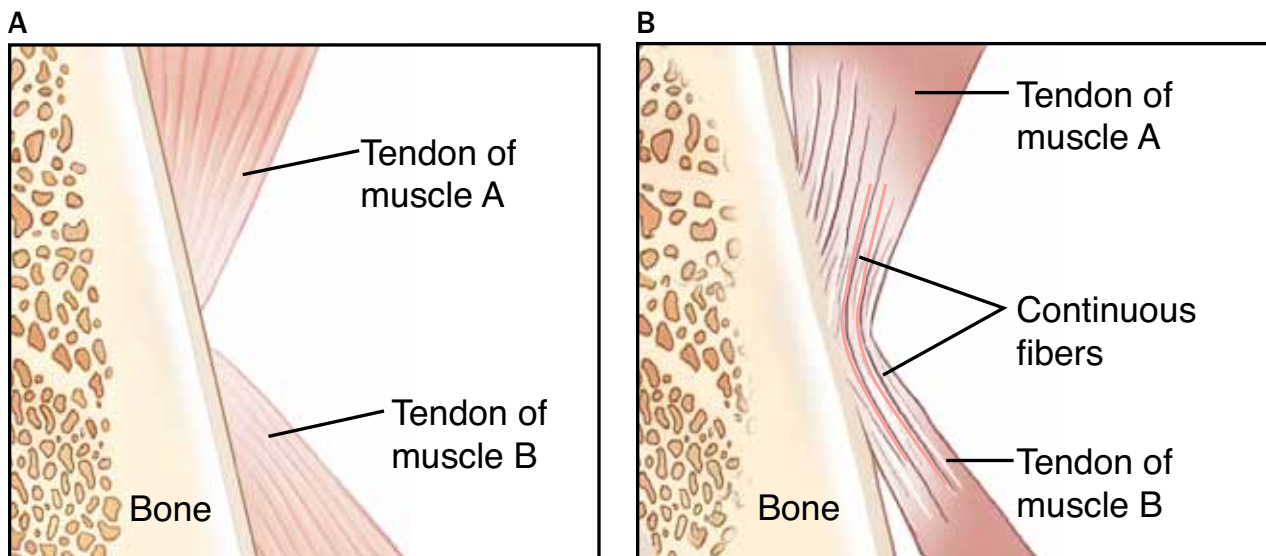
stop here. Just when we think that we see the big picture, there is often an even *larger* picture to appreciate. This even bigger picture involves placing muscles into the fascial webbing that traverses the entire body (FIGURE 1). Looking at the muscular system in this manner requires us to look at patterns of muscle groupings that extend beyond the local joint(s) where, we learned, each of the muscle has its actions. To best understand how muscles fit into the fascial web of the body, we need to look at the body from the perspective of fibrous fascial connective tissue.

The term fascia literally means bandage. Like a bandage, fibrous fascia creates a web that wraps around structures of the body, providing a continuum that connects these structures to the rest of the body. The fascial web truly forms the structural framework that unites the entire human body.

Looking at the body from this fascial perspective, we can see that fascia provides the framework for all other tissues to form. If bone cells (osteocytes) lay down bone matrix within a fascial sleeve, a bone is formed within fascial periosteum. If nerve cells (neurons) are formed within fascial sleeving, the brain and spinal cord are formed within meninges, and peripheral nerves are formed within sleeves of endoneurium, perineurium, and epineurium.

### MYOFASCIAL UNITS

In our area of focus, if muscle cells are created within



**Figure 3A.** The classic understanding of a muscle attachment is that all the tendinous fibers end at the bony attachment, and are discrete from adjacent musculature. **B,** In reality, most tendinous attachments of muscles have some fibers that are continuous with adjacent muscles.

endomysium, perimysium and epimysium sleeves, muscles are formed. In fact, our usual division of a muscle and its tendon (or aponeurosis) is a virtual myth. The tendon of a muscle is actually the coalescing of all the endomysia, perimysia and the epimysium at the ends of the muscle. These fascial structures wrap around every individual muscle fiber, every muscle bundle (fascicle) and the entire muscle itself. In other words, the fascial tissue that creates the tendon/aponeurosis is integral to and pervades the entire muscle belly. In fact, a better term than muscle for this structure would be myofascial unit, because it describes the nature of the structure as having muscular and fascial components that are inextricably bound into one indivisible unit (FIGURE 2).

### MYOFASCIAL MERIDIANS

But looking at muscles as myofascial units still misses the bigger picture of the myofascial system, because even these myofascial units are not truly independent units. Rather, they are linked to other myofascial units in the form of myofascial meridians. The classic representation of muscles is that they have discrete attachment points on bones. By this model, each of the muscles is independent of one another (FIGURE 3a).

However, this is rarely the case. Far more often, even though some of the fascial tendinous fibers of the muscle do attach into and end at the attachment bone, other fascial tendinous fibers go beyond the bony attachment site and are continuous with the fascial tendinous fibers of the adjacent muscle (FIGURE 3b). In this manner, these muscles/myofascial units are linked to each other.

Examining the fascial connections between muscles allows us to discern specific lines of linkage that travel throughout the body. These lines are called myofascial meridians. Each myofascial meridian is a somewhat discrete aspect of the fascial web that travels and connects far reaches of the body.

**“TO BEST UNDERSTAND HOW MUSCLES FIT INTO THE FASCIAL WEB OF THE BODY, WE NEED TO LOOK AT THE BODY FROM THE PERSPECTIVE OF FIBROUS FASCIAL CONNECTIVE TISSUE.”**

Hence, structurally, a myofascial meridian can be defined as a linear series of muscles/myofascial units interconnected within the fascial webbing of the body (FIGURE 4). Because each myofascial unit functions to create pulling force (the essence of muscle function is that muscles create pulling forces), a myofascial meridian acts to transfer the pulling force of one muscle to the other muscles of the meridian. Further, if a muscle is stretched, the pulling force of this stretch can also be transmitted through the meridian.

Therefore, a myofascial meridian is effectively a line that transmits tension (pulling) forces throughout the body. This tension transfers sequentially from one myofascial unit of the meridian to the next. Like the concept

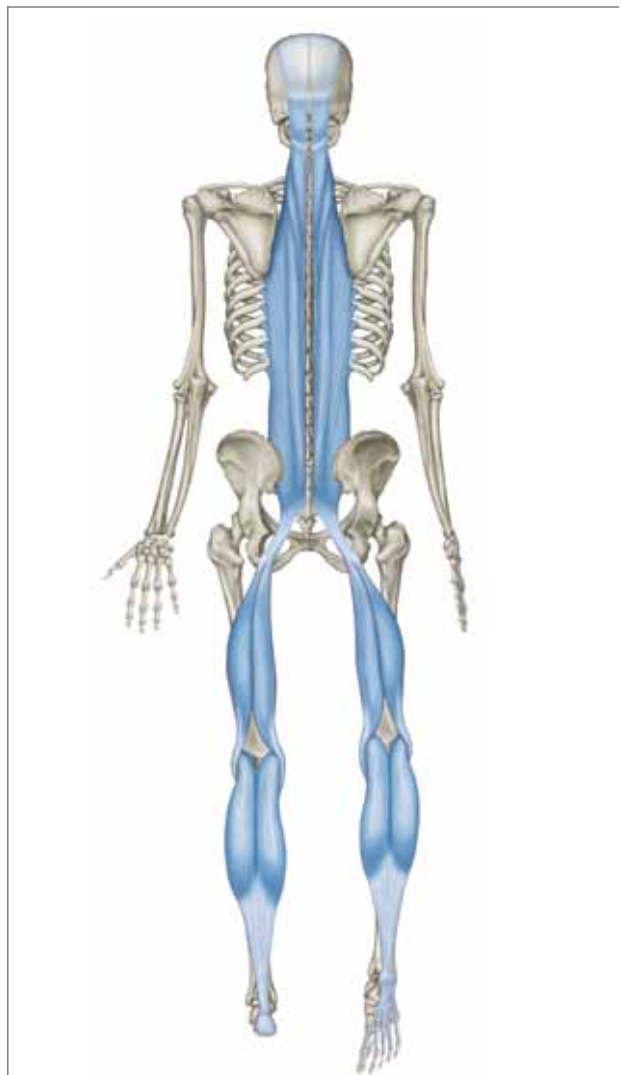

Figure 4. Illustration of the superficial back line myofascial meridian.

CREDIT: Myers, T: Anatomy Trains, 2ed. 2009, Elsevier

of dominoes falling, the tension created at one end of a myofascial meridian can be transferred all the way to the other end.

For example, in the superficial back line (see FIGURE 4), if the triceps surae (gastrocnemius and soleus) are tight, that tension can be transferred to the adjacent hamstrings via their fascial connection across the knee joint (FIGURE 5). From there, the tension could be transmitted up through the sacrotuberous ligament to the thoracolumbar fascia and the erector spinae group (See FIGURE 4).<sup>1</sup>

### APPLICATION OF MYOFASCIAL MERIDIANS

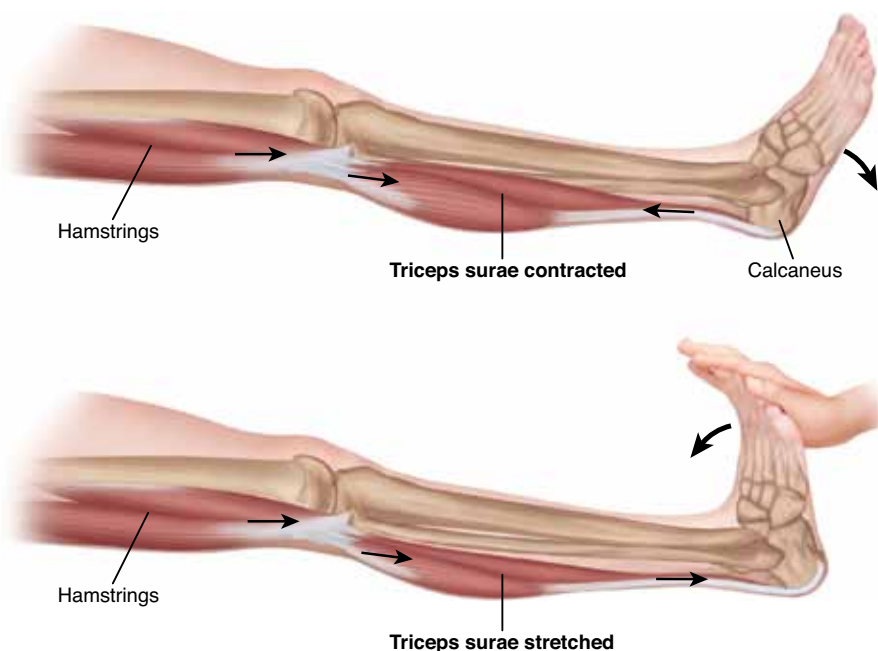
Concepts such as these are intellectually stimulating, but they also have practical value when they are applied to clinical orthopedic massage. Application can be made to assessment and treatment.

When performing assessment, understanding myofascial meridians alerts us to the fact that a tension that is occurring in one region of the client's body could be originating from a distant location within their body. Us-

ing the myofascial meridian map, we can trace where these distant sites might be.

For example, if the client is experiencing tension within the rhomboids on the left side of the body, their location within the spiral line myofascial meridian would make it wise for a massage therapist to assess the ipsilateral (same-side) serratus anterior, as well as the contralateral (opposite-side) splenius capitis and cervicis. In fact, given that tension can travel throughout the spiral line, we should assess the myofascia of the entire line, from the head to the foot and back up to the head again (FIGURE 6). Thus, we begin by assessing locally at the symptomatic region, and then broaden out to look at the body globally.

When it comes time for treatment, if we have found that the cause of the problem is either partially or entirely due to strains/tension from other myofascial units within the spiral line, then true and lasting improvement can only come if those areas are treated. Although preset cookbook routines are rarely the basis of effective clinical work, addressing the entire myofascial meridian

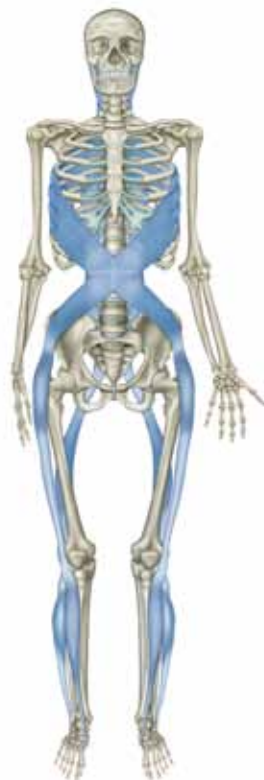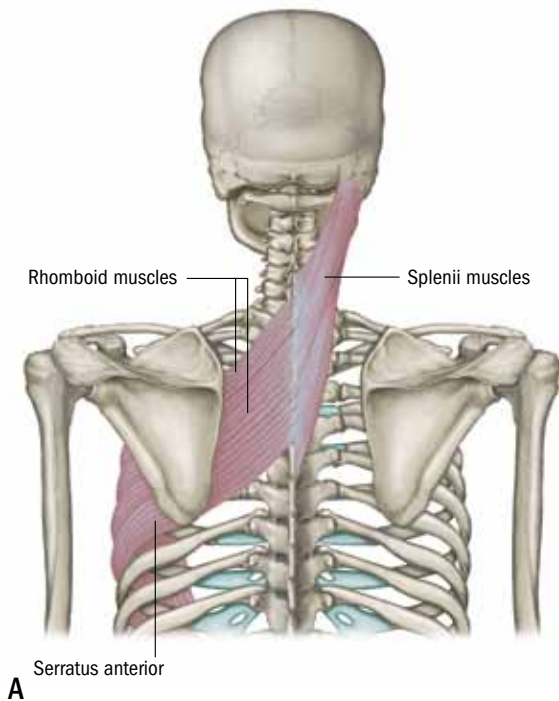


**Figure 5A.** When the triceps surae (gastrocnemius and soleus) contracts, because of their fascial continuum across the knee joint, the tension (pulling force) of their contraction is transferred to the hamstrings. **B.** Similarly, if the triceps surae is stretched, the tension of this stretch is transferred across the knee joint to the hamstrings.

CREDIT : Illustrated by Giovanni Rimasti

<sup>1</sup> Through the painstaking, creative, and innovative work by Tom Myers, twelve major myofascial meridians (also called anatomy trains), have been mapped in the body. For a full treatise on myofascial meridians, see *Anatomy Trains*, 2ed., 2009, by Tom Myers. Published by Churchill Livingstone of Elsevier. Also of tremendous value when examining the concepts of myofascial continuity is the integrative anatomy work of Gil Hedley ([www.gilhedley.com](http://www.gilhedley.com)).





**B** Figure 6A, Within the spiral line myofascial meridian, the rhomboids are connected to the same-side serratus anterior and the opposite-sided splenius capitis and cervicis muscles. **B**, An anterior view of the entire spiral line.

CREDIT: Myers, T: Anatomy Trains, 2ed. 2009, Elsevier

of a tight component muscle might generally be a good idea. Similar to assessment, we begin by working locally at the symptomatic region, but based on the assessment findings, we might then broaden out to work the body more globally. In effect, we employ anatomy and we then reverse anatomy.

#### LIMITS OF MYOFASCIAL TRANSFER OF TENSION

Although myofascial meridian theory posits that tension and strain can be transmitted throughout the entire length of a meridian, you need to remember that this does not necessarily occur. Similar to the ripples created when throwing a rock in a pond, the pulling force of a tight muscle within a myofascial meridian will likely lessen with distance along the meridian. The determining factor for how tension is transmitted is based on how tight the component muscles are within the meridian.

For example, if muscle A is tight, but muscle B is loose, then the tension force of muscle A will likely be absorbed by muscle B. The result is that the next muscle in the meridian, muscle C, will not feel the effects of muscle A being tight. However, if in this same scenario muscle B is also tight, then the tension of muscle A being tight will be transferred through muscle B, all the way to muscle C. Then it follows that if muscle C is tight, the tension would continue to muscle D, and so on. Therefore, as a general rule, far-reaching effects through myofascial meridians are less likely to occur in clients who are generally loose, but would likely be more pronounced in clients who are generally tight.

As we seek to become more proficient with clinical orthopedic massage, the responsibility to better understand principles of anatomy and physiology increases. However, the critical thinking necessary to apply these principles to client assessment and treatment demands that we both learn the body's separate pieces, as well as how to reverse anatomy and assemble them back together. Only by reversing anatomy to see and understand the big picture, can our clinical skills improve to meet the demands of clinical orthopedic work. ■



*Joseph E. Muscolino, DC, has been a massage therapy educator for 25 years and currently teaches anatomy and physiology at Purchase College. He is the owner of The Art and Science of Kinesiology in Stamford,*

*Connecticut, and the author of The Muscle and Bone Palpation Manual, The Muscular System Manual and Kinesiology, The Skeletal System and Muscle Function textbooks (Elsevier, 2009, 2010 and 2011). Visit Joseph's website at [www.learnmuscles.com](http://www.learnmuscles.com).*