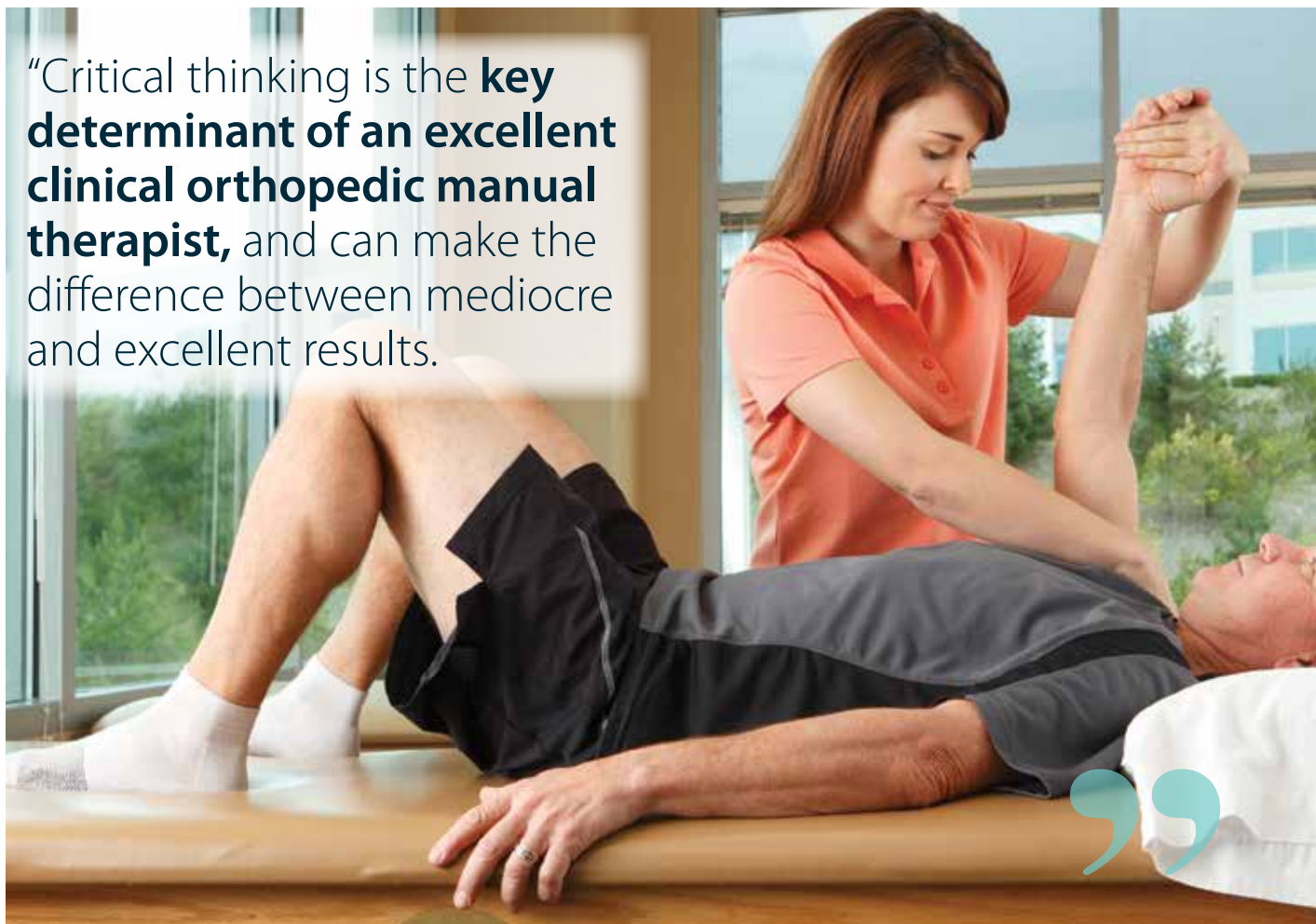


# Body Mechanics

by Joseph E. Muscolino | Art Giovanni Rimasti | Photography Yanik Chauvin



“Critical thinking is the **key determinant of an excellent clinical orthopedic manual therapist**, and can make the difference between mediocre and excellent results.



## The Importance of Joint Mobilization

Many factors are important for musculoskeletal health. Arguably, the two most important factors are flexibility of soft tissue and strength of musculature. Although strength of musculature is often beyond the scope of massage therapy, massage therapists excel at increasing soft tissue flexibility. In this regard, massage therapy holds an extremely important place in the world of clinical orthopedic manual therapy.

Often the key to remedying a client's musculoskeletal condition is loosening tight soft tissues that directly cause pain and/or decrease the client's range of motion (ROM). Unfortunately, for many years, the field of massage therapy has limited its effectiveness by focusing only on tight musculature. With the recent understanding and acceptance of the importance of fascia and the role that fascial adhesions (and fascial contraction) can play in a client's condition, the field of

*Before practicing any new modality or technique, check with your state's or province's massage therapy regulatory authority to ensure that it is within the defined scope of practice for massage therapy.*

massage therapy has been expanding its focus. This is an excellent step forward for manual therapy.

### INTRINSIC FASCIAL TISSUE

However, this increased focus on fascial tissue has largely limited itself to myofascial tissue (via Myers' work with myofascial meridians/anatomy trains) and subcutaneous fascia (via the Stecco family's work on superficial fascial tissue/membranes). As a result, most massage therapists still largely ignore an incredibly important fascial tissue component of the body: joint capsules and their associated intrinsic joint ligaments.

After all, tautness in any soft tissue will decrease motion and impact the quality of the client's life. This is true whether the taut soft tissue is muscle myofascia, subcutaneous fascia, or intrinsic capsular/ligamentous fascial tissue. Therefore, if our goal is to increase soft tissue flexibility, loosening muscles and their associated myofascial and subcutaneous fascial tissues while ignoring intrinsic fascial joint tissue may be an excellent job halfway-done—and may likely be the reason for limited success when treating a client's musculoskeletal condition.

The province of intrinsic fascial tissues has been largely left to chiropractic and osteopathic physicians. Yet, if massage therapy is to take its rightful place as the preeminent manual therapy for clinical orthopedic manual treatment of soft tissue myofascioskeletal conditions, then learning how to treat intrinsic joint tissues needs to become a part of the treatment strategy. Toward this end, joint mobilization, specifically Grade IV joint mobilization, can be an extremely important technique to incorporate into the treatment strategy for our clients. And when properly learned, is effective and safe.

### JOINT MOBILIZATION

Joint mobilization is actually quite simple to perform. It involves pinning/stabilizing one bone at a joint, and then moving/mobilizing the adjacent bone relative to it. In effect, joint mobilization is identical to a treatment method that is already prevalent in the world of massage therapy: pin-and-stretch technique. Pin-and-stretch as it is performed involves pinning within the belly of a muscle and then stretching one of the muscle's attachments away from the pinned point. This has the effect of focusing the stretch to the part of that muscle that is located between the pinned point and the attachment that is moved. With joint mobilization technique the therapist instead pins one bone at a joint, and then moves the other bone of the joint away from it, thereby focusing the stretch to the intrinsic capsular/ligamentous tissue (as well as any deep intrinsic musculature) located between those two bones (Figure 1). Both techniques involve pinning and stretching, in other words, pinning and mobilizing. With typical pin-and-stretch we focus our mobilization on muscular tissue; with Grade IV joint mobilization we focus our mobilization on intrinsic joint fascial tissue.

### TECHNIQUE GUIDELINES

As with any technique, there are guidelines for the efficient and safe employment of joint mobilization.

- Most typically, the proximal bone is pinned and the distal bone is stabilized.
- When placing the pin to stabilize the bone, it is important to find a bony surface that is as broad and flat as possible; this ensures that the bone is securely and comfortably held.
- It is important to also find a broad and flat surface on the bone that

is being mobilized so that it is securely and comfortably contacted.

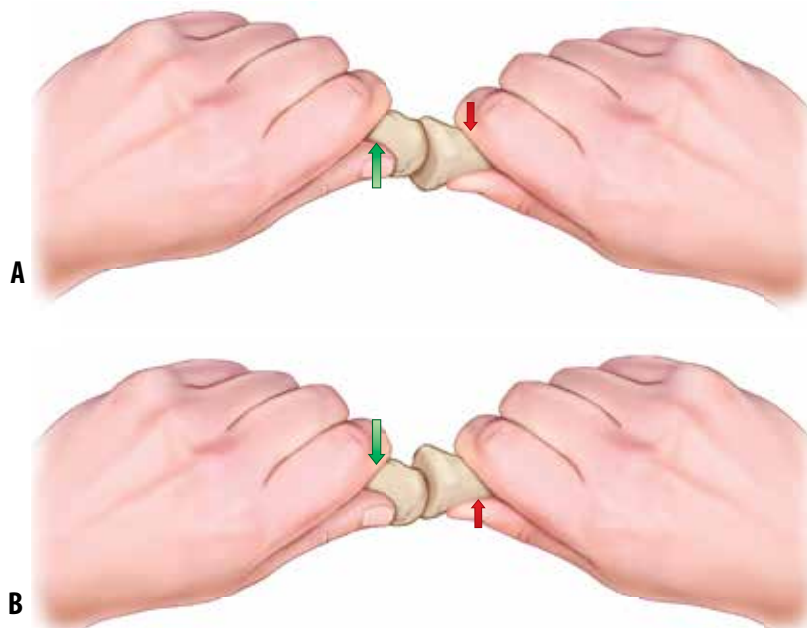
- It is usually optimal to contact each bone as close to the joint surface as possible. This is especially important for nonaxial motion joint mobilization.
- If the skin and other overlying soft tissue is loose, a *soft tissue pull* might be necessary. A soft tissue pull is accomplished by first contacting the client proximal to the desired stabilization point and then pulling the skin and subcutaneous fascia toward that point. This ensures that any soft tissue slack is removed so that your grasp is secure on the underlying bone.
- First adding traction to the joint adds to the efficiency of the mobilization.
- The actual mobilization is usually done by performing 3-5 oscillations.
- The oscillation motion is performed slowly; *a fast thrust is never involved*.
- The excursion of the oscillation is very small, usually only a few millimeters.
- Each oscillation is held for a fraction of a second and then released.

### INDICATIONS/CONTRAINDICATIONS

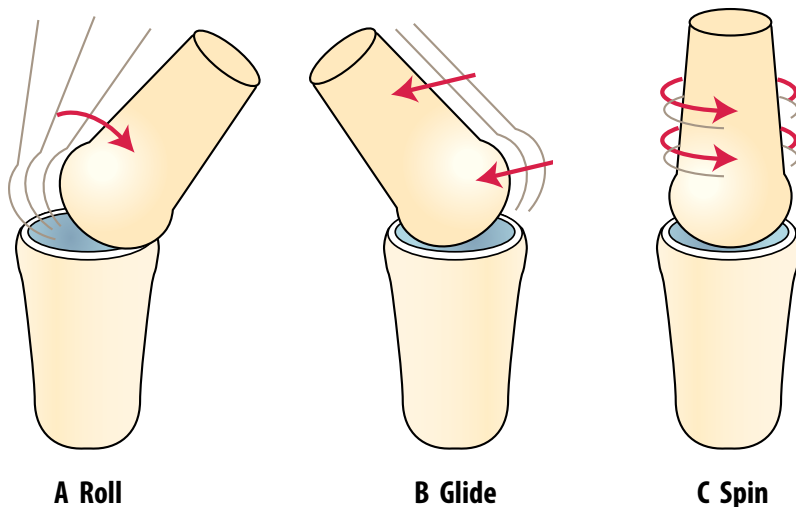
The indication for joint mobilization is simple. Given that the goal of this technique is to increase motion at a joint, the indication is joint hypomobility: if the joint's motion is decreased as a result of taut intrinsic joint tissues, joint mobilization is indicated. The contraindication to joint mobilization is joint hypermobility: if the joint's motion is excessive due to slackened tissue or if the integrity of the tissue is compromised or unstable, joint mobilization is contraindicated.

### MOTION PALPATION ASSESSMENT

Joint hypomobility or hypermobil-



**Figure 1** Joint mobilization is performed by pinning one bone and mobilizing the adjacent bone relative to it, thereby stretching the intrinsic soft tissues located between them.



**Figure 2** Fundamental motions of roll, glide, and spin. A, Roll. B, Glide. C, Spin. (Figure reproduced with permission from Elsevier, *Kinesiology, The Skeletal System and Muscle Function*, 2<sup>nd</sup> Edition, JE Muscolino)

“The term joint mobilization is actually a broad term that may be defined in many ways. **One classification of joint mobilization divides it into five grades.**”



ity is determined by an assessment technique known as *motion palpation*. Motion palpation assessment is performed in an identical manner to joint mobilization treatment technique; in other words the joint is challenged to move into its joint play ROM at the end of its passive ROM, and the quality of the *end-feel* motion is felt.

- If the end-feel is hard and abrupt and the motion is felt to be restricted, the joint is hypomobile and joint mobilization is indicated.
- If the end-feel is mushy and the joint exhibits excessive motion, the joint is hypermobile and joint mobilization is contraindicated.
- A gentle bounce or spring to the end-feel is optimal and indicates a healthy joint. In this case, joint mobilization is neither indicated nor contraindicated, but may be performed proactively to maintain healthy joint motion.

Palpating for the quality of end-feel motion can be subtle and challenging to discern at first. As with any technique, practice and focused attention are the keys to becoming skilled at motion palpation assessment and joint mobilization treatment techniques.

#### AXIAL AND NONAXIAL MOTIONS

The type of motion that is performed during the mobilization can be axial, nonaxial, or a combination of the two. Therapists often think of joint motion only in terms of axial motion. For example, the glenohumeral joint motions that are usually taught are flexion and extension in the sagittal plane, abduction and adduction in the frontal plane, and lateral and medial rotations in the transverse plane. All of these motions are described as axial because they involve the humerus moving in a circular manner around an axis

# Grading Joint Mobilization

THE TERM JOINT MOBILIZATION IS ACTUALLY A BROAD TERM THAT MAY BE DEFINED IN MANY WAYS. ONE CLASSIFICATION OF JOINT MOBILIZATION DIVIDES IT INTO FIVE GRADES.

**Grade I:** Slow, small-amplitude movement performed at the beginning of a joint's active/passive ROM.

**Grade II:** Slow, large-amplitude movement performed through the joint's active ROM.

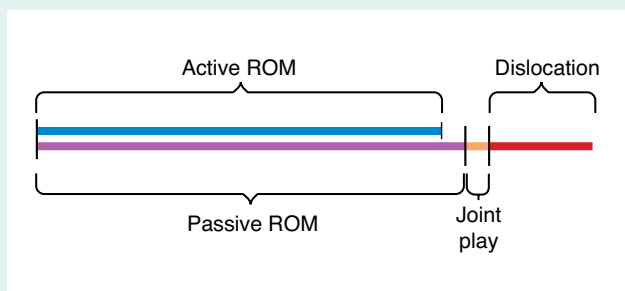
**Grade III:** Slow, large-amplitude movement performed to the limit of the joint's passive ROM.

**Grade IV:** Slow, small-amplitude movement performed at the limit of a joint's passive ROM, and into resistance (joint play) (see accompanying Figure).

**Grade V:** Fast, small-amplitude movement performed at the limit of a joint's passive ROM, and into resistance/joint play.

In this grading system, Grade I is any beginning ROM at a joint; Grade II is the client's active ROM; and Grade III is a typical stretch that is performed by a therapist on a client (or a self-care stretch performed by the client himself/herself) to the end of passive range of motion. Grade IV is joint mobilization as the term is used in this article. It involves stretching the soft tissues at a joint such that the joint is challenged to move past its passive ROM into the range of motion that is known as joint play.

**Note:** It should be pointed out that Grade V joint mobilization is a chiropractic/osteopathic high-velocity (fast thrust) manipulation that is not within the scope of practice for massage therapy.



(Figure reproduced with permission from Elsevier, *Kinesiology, The Skeletal System and Muscle Function*, 2<sup>nd</sup> Edition, JE Muscolino)

## Caution

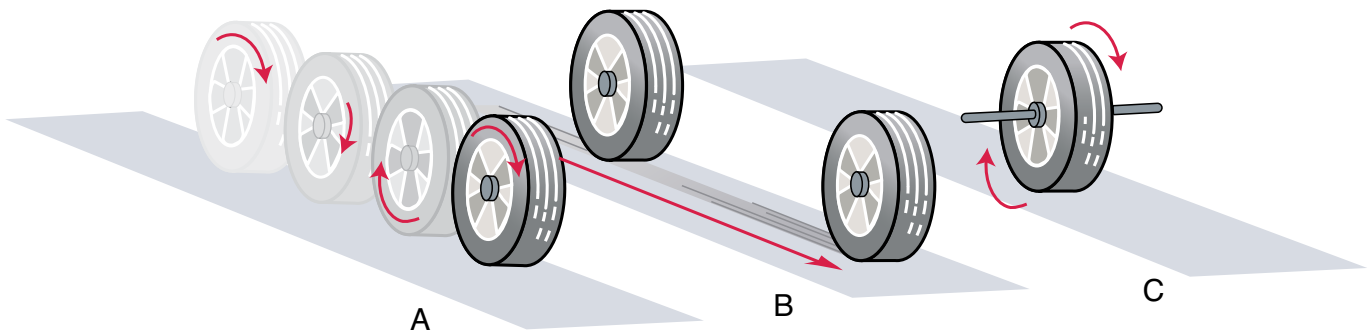
Before practicing any new modality or technique, check with your state's or province's massage therapy regulatory authority to ensure that it is within the defined scope of practice for massage therapy. Grade IV joint mobilization is within the scope of practice for massage therapy in most (but not all) states in the US.

Further, it is critical that you understand, study, and practice Grade IV joint mobilization technique carefully before attempting to use it with your clients. The steps of joint mobilization are actually quite simple, and this article provides an excellent conceptual framework and set of guidelines for performing this technique. However, the challenge lies in practicing the technique sufficiently to develop a refined sense of joint motion before using it with your clients. For this reason, it is strongly recommended to attend in-person workshops with experienced continuing education instructors before incorporating this technique into your practice.

Any technique that has the power to help also has the power to do harm, and joint mobilization is an extremely powerful technique. Joint mobilization, when applied inappropriately, can cause serious harm to the client. Inappropriate application of joint mobilization technique includes applying joint mobilization to a condition for which it is contraindicated, most likely an unstable/hypermobile joint or to tissue that does not have sufficient integrity. It also includes applying joint mobilization to a condition for which its use is indicated, but executing the technique incorrectly—for example, performing it too forcefully.

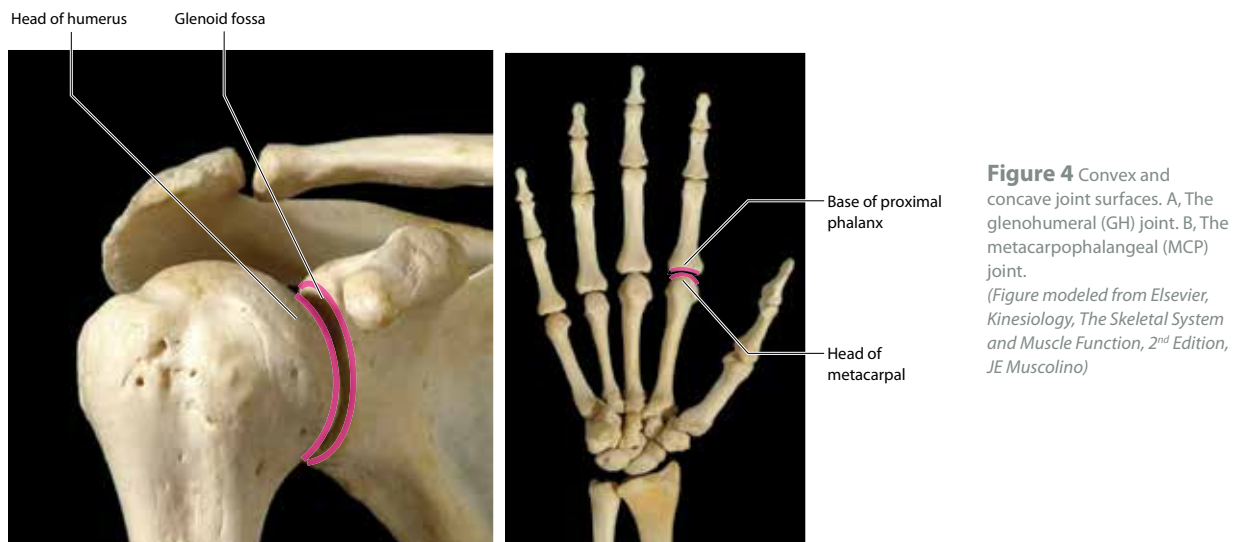
If you have any doubt about whether it is appropriate to use joint mobilization for a particular client, be sure first to obtain written permission from the client's chiropractic or allopathic physician.

It is also extremely important to emphasize that a fast thrust should never be employed when performing joint mobilization. A fast thrust defines a Grade V joint mobilization and is not within the scope of practice of massage therapy in the United States.



**Figure 3** Roll, glide, and spin motions: tire analogy. A, Tire that is rolling along the road. B, Tire that is gliding/skidding along the road. C, Tire that is spinning in place on the road.

(Figure reproduced with permission from Elsevier, *Kinesiology, The Skeletal System and Muscle Function, 2<sup>nd</sup> Edition, JE Muscolino*)



**Figure 4** Convex and concave joint surfaces. A, The glenohumeral (GH) joint. B, The metacarpophalangeal (MCP) joint. (Figure modeled from Elsevier, *Kinesiology, The Skeletal System and Muscle Function, 2<sup>nd</sup> Edition, JE Muscolino*)

of rotation that passes through the joint. However, underlying most axial motions such as flexion or abduction are more fundamental component motions called roll, glide, and spin. To perform joint mobilization, these fundamental motions of roll, glide, and spin must first be understood (Figure 2).

### ROLL, GLIDE, AND SPIN

Spin and roll are axial motions, but roll must occur in conjunction with glide, which is a nonaxial motion. It is this nonaxial glide motion that joint mobilization is usually focused on. To visualize these three fundamental motions, it can be helpful to make an analogy to a car tire. Roll motion would be equivalent to a tire that is rolling along the road. Glide motion is equivalent to a tire that is

skidding along the road. And spin is the tire spinning in place on the surface of the road (Figure 3).

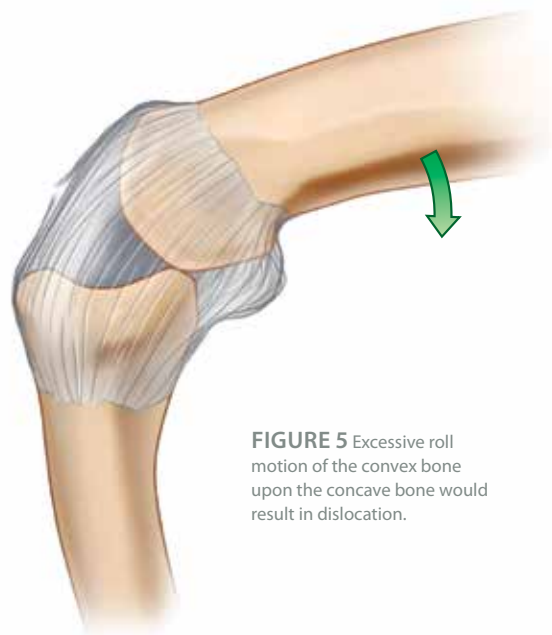### CONVEX/CONCAVE KINEMATICS

Now that roll and glide motions are understood, let's apply this knowledge to convex/concave kinematics. This will allow us to determine how to assess and mobilize the nonaxial glide component of joint motion to improve the ROM of the joint. The term *kinematics* simply means *motion*; in the world of kinesiology, it refers to joint motion. *Convex/concave* kinematics refers to the motion pattern that occurs at a joint where in one bone has a convex shape and the other bone has a concave shape.

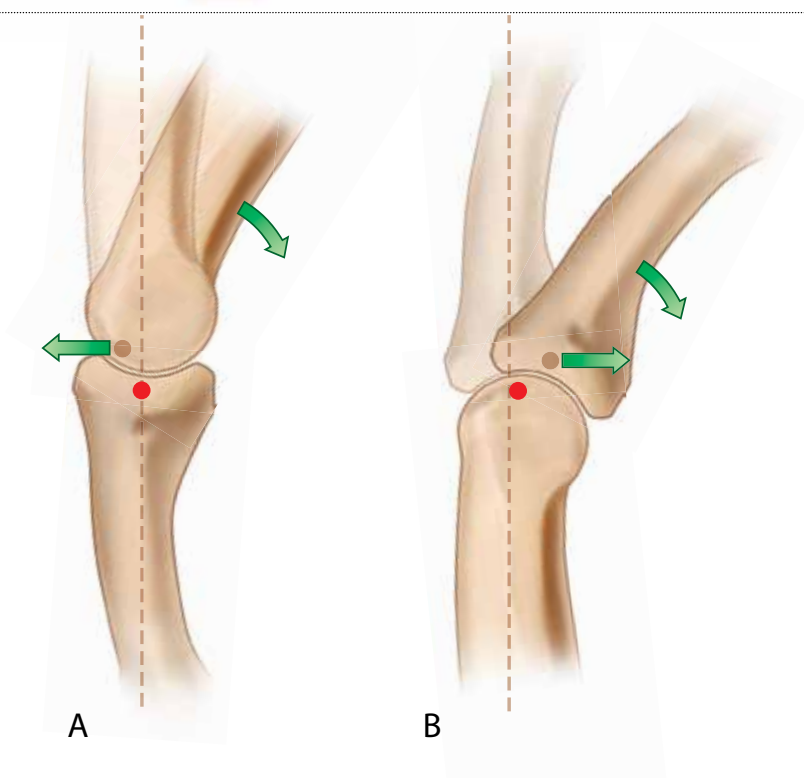
At many joints, the proximal bone is concave and the distal bone is convex. Examples include the gleno-

humeral (GH) and hip joints. Looking more closely at the GH joint, the proximal bone, the glenoid fossa of the scapula, is concave; and the distal bone, the head of the humerus, is seen to be convex. At other joints, the proximal bone is convex and the distal bone is concave. Examples include the metacarpophalangeal (MCP) and metatarsophalangeal (MTP) joints. Looking more closely at the MCP joint, the proximal bone, the head of the metacarpal, is convex and the distal bone, the base of the proximal phalanx, is concave (Figure 4).

When the convex bone moves relative to the concave bone, we have *convex on concave kinematics*; and when the concave bone moves relative to the convex bone, we have *concave on convex kinematics*.



**FIGURE 5** Excessive roll motion of the convex bone upon the concave bone would result in dislocation.



**FIGURE 6** Kinematics of roll and glide. A, Convex on concave kinematics: Roll of the convex (upper bone) in one direction is accompanied by glide of the convex bone in the opposite direction. B, Concave on convex kinematics: Roll of the concave (upper) bone in one direction is accompanied by glide of the concave bone in the same direction.

“The fundamental kinematics of joint motion may seem theoretical, but are actually quite valuable.”

tics. Given that most joint motions are standard *open-chain* motions in which the distal end of the extremity is free to move and the proximal end is more stable, convex on concave kinematics or concave on convex kinematics is usually determined by the shape of the distal bone at the joint.

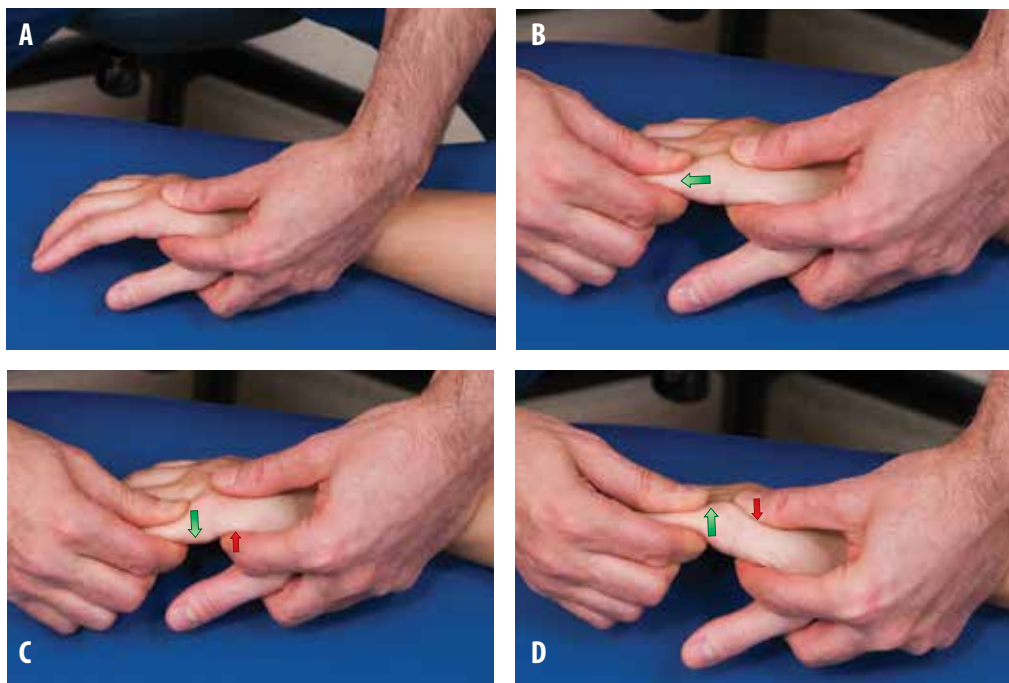
### ROLL AND GLIDE KINEMATICS

Now let's apply roll and glide motions to convex/concave kinematics. When a convex-shaped bone begins to roll on a concave-shaped bone, it rolls along the concave bone's articular surface, much like the tire in Figure 3A rolled along the road. However, whereas a tire has unlimited road to roll along, the path of the concave joint surface is limited. So if the convex bone were to roll too far, it would roll right off the concave joint surface and dislocate (Figure 5).

Joints are designed to operate optimally when the opposing articular surfaces are centered on one another, a concept that is often referred to as *centration*. Therefore, it is important for the bones to stay centered in proper alignment with each other. This is where glide is needed to accompany roll. As the convex bone rolls along the concave bone in one direction, nonaxial glide must occur in the opposite direction so that centration is maintained (Figure 6A).

If instead we look at a concave bone moving along a convex bone, the kinematics change. Excessive roll of the concave bone on the convex bone would also result in dislocation, but here the compensatory glide is different. Now the glide must be in the same direction as the roll to maintain the centration of the joint (Figure 6B).

Thus, with convex on concave kinematics, roll in one direction is accompanied by glide in the opposite



**FIGURE 7**  
Mobilization of metacarpophalangeal (MCP) joint glides in the sagittal plane. A, Stabilization of the metacarpal. B, Traction of the proximal phalanx. C, Palmar glide mobilization of the proximal phalanx. D, Dorsal glide mobilization of the proximal phalanx. (Figure reproduced with permission from Joseph E. Muscolino)

direction; and with concave on convex kinematics, roll in one direction is accompanied by glide in the same direction. In either case, if adhesions within the intrinsic fascial tissues of the joint restrict the nonaxial glide component of joint motion, centration cannot be maintained, thereby increasing the chance of limited motion (joint dysfunction) and injury.

The fundamental kinematics of joint motion may seem theoretical, but are actually quite valuable. With an understanding of joint kinematics, the therapist can critically reason how motion should occur at a joint. This empowers the therapist to be able to critically think how to apply joint mobilization treatment technique to their client's condition instead of memorizing cookbook treatment routines. Critical thinking is the key determinant of an excellent clinical orthopedic manual therapist, and can make the difference between mediocre and excellent results.

#### JOINT MOBILIZATION EXAMPLES

To ground this theory in actual prac-

tice, the following examples demonstrate joint mobilization technique performed at joints of the upper extremity, lower extremity, and axial skeleton. In each example, the steps to be performed are outlined.

#### EXAMPLE 1: Metacarpophalangeal Joint Glide

Sagittal plane glide motions of the metacarpophalangeal (MCP) joint of the index finger involve concave on convex kinematics. Flexion is composed of an anterior/palmar roll of the phalanx accompanied by a palmar glide of the phalanx. And extension is composed of a posterior/dorsal roll of the phalanx accompanied by a dorsal glide of the phalanx. Therefore, palmar glide mobilization is needed to optimize flexion range of motion; and dorsal glide mobilization is needed to optimize extension range of motion.

Following are the steps to perform palmar and dorsal glide mobilizations of the MCP joint:

1. Use one hand to pin/stabilize the distal end of the metacarpal on its

dorsal and palmar surfaces (Figure 7A).

2. Add traction to the joint by gently pulling the phalanx away from the metacarpal (Figure 7B).

3. Challenge the phalanx to glide in the palmar direction until tissue tension is reached; and then gently increase the palmar glide force to mobilize the joint (Figure 7C).—Three to five gentle mobilization oscillations are performed, each one performed slowly with an excursion of only a few millimeters and held for a fraction of a second.

4. Challenge the phalanx to glide in the dorsal direction until tissue tension is reached; and then gently increase the dorsal glide force to mobilize the joint (Figure 7D).—Three to five gentle mobilization oscillations are performed, each one performed slowly with an excursion of only a few millimeters and held for only a fraction of a second.

#### EXAMPLE 2: Talocrural Joint Traction

Long axis traction of the ankle (talocrural) joint. This is a fairly simple example of nonaxial joint mobiliza-

# Joint Crepitus

When performing joint mobilization, it is common to hear or feel a sound emanating from the joint. Any sound that occurs during joint motion is termed joint crepitus. Although therapists and clients are often concerned by the presence of joint crepitus, it seldom indicates a serious condition and rarely contraindicates joint mobilization technique. In fact, joint crepitus may be an indicator that mobilization should be performed.

To determine whether joint crepitus indicates or contraindicates joint mobilization technique, it is important to determine the mechanism/cause of the crepitus because it can occur for many reasons. (Keep in mind that whether joint crepitus is present or not, the two most important criteria for the indication/contraindication of joint mobilization technique are the mobility of the joint and the structural integrity of the joint tissues.)

## FOLLOWING ARE THE MOST COMMON CAUSES OF JOINT CREPITUS:

**JOINT RELEASE:** This is the sound that is often heard when a chiropractic manipulation is performed. A joint release sounds similar to the popping noise that a cork makes when it is removed from a bottle of champagne. Unlike other types of joint crepitus, a joint release cannot occur multiple times in succession at the same joint as other forms of crepitus can. This is a good criterion to use to determine if the joint crepitus you hear is a joint release. If a joint release does occur, there is no need for concern. In fact, it is likely a good sign because it shows that motion has been introduced into the joint. Note: Although a joint release may occur during Grade IV mobilization, it should not be the intended goal of this mobilization technique).

**TAUT SOFT TISSUE RESTRICTION:** Joint crepitus is most often caused by a hypomobility of the joint due to a taut band of soft tissue. As a joint moves through its range of motion, it might reach a point where the taut band of soft tissue restricts its further motion. In effect, it becomes temporarily stuck, often along a bumpy contour of underlying bone. The continued application of force can then move the joint past this restriction, resulting in a clicking type of noise, as the taut band rubs (twangs) over the underlying bony contour. This type of crepitus would be assessed by the presence of decreased motion, in other words, a joint hypomobility. Joint hypomobility indicates joint mobilization technique, so mobilization should be performed when crepitus occurs for this reason because it can serve to gradually loosen the taut soft tissue.

**EXCESSIVELY LOOSE SOFT TISSUE:** A hypermobile joint that has excessively loose soft tissue can also cause joint crepitus. This occurs as the excessive motion allows bands of soft tissue to rub/twang along bumps on the underlying bones. This type of crepitus would be assessed by the presence of excessive motion, in other words, joint hypermobility. Because joint hypermobility contraindicates joint mobilization technique, joint mobilization should not be performed when crepitus occurs for this reason.

**DEGENERATIVE JOINT SURFACE:** If there is degeneration of the articular cartilage surfaces of the joint (indicative of degenerative joint disease [DJD], also known as osteoarthritis [OA]), mobilization of the joint can cause the rough surfaces to grind along each other, creating joint crepitus. This type of joint crepitus sounds/feels similar to rubbing sandpaper along a surface. Unlike other causes of joint crepitus, this type of crepitus is often accompanied by pain or discomfort deep in the joint. This type of joint crepitus usually contraindicates joint mobilization because it would cause further irritation to the joint. However, if traction can be added to the mobilization so that the joint surfaces do not grind along each other, mobilization can be performed and may be helpful toward mobilizing a joint that otherwise cannot be moved without pain.

tion in which the talus is tractioned away from the tibia and fibula.

Following are the steps to perform this mobilization:

1. Use both hands (middle finger reinforced over middle finger) to contact the dorsal surface of the talus immediately distal to the tibia/fibula (Figure 8A). No stabilization hand is needed because the client's body weight serves to stabilize the rest of the body, including the tibia and fibula.
2. Add traction to the joint by gently pulling the talus away from the tibia/fibula until tissue tension is reached; and then gently increase the traction force to mobilize the joint (Figure 8B). – Three to five gentle mobilization oscillations are performed; each one is performed slowly with an excursion of only a few millimeters and held for only a fraction of a second.

### EXAMPLE 3:

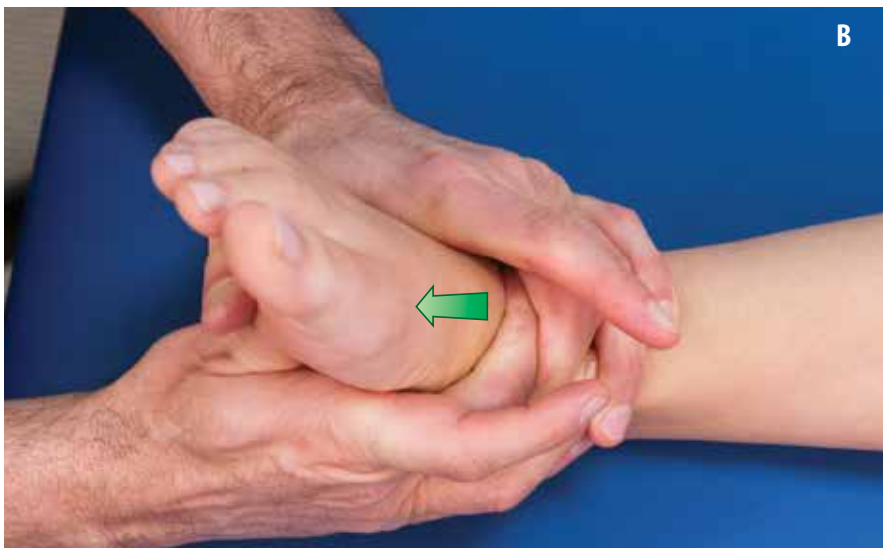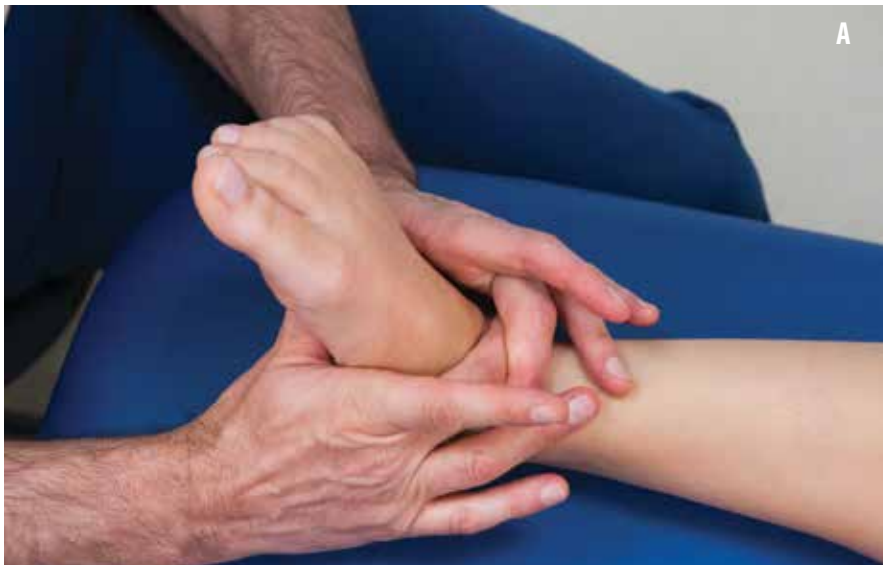#### Glenohumeral Joint Roll and Glide

Frontal plane roll and glide mobilization of GH joint abduction involves convex on concave kinematics. Abduction involves a superior roll of the humeral head accompanied by an inferior glide of the humeral head. This roll and glide mobilization is performed from the starting position of ninety degrees of humeral abduction.

Following are the steps to perform this mobilization:

1. Place one hand on the medial surface of the distal humerus and the other hand on lateral surface of the proximal humerus (Figure 9A). Note: It is logistically difficult to use one's hands to stabilize the scapula for this mobilization. Instead, when applying the force to mobilize the humerus into inferior glide, the "slack" of scapular depression motion needs to be first taken out. When pressing inferiorly on the humeral head, the shoulder girdle will





**FIGURE 8** Traction mobilization of ankle (talocrural) joint. A, Contacting the talus. B, Traction mobilization of the talus. (Figure reproduced with permission from Joseph E. Muscolino)

## Integrating Joint Mobilization into your Massage Session

Because joint mobilization is effectively a type of stretching, its integration into a massage session should be done when regular (Grade III) stretching would be done; that is after the associated soft tissues have first been warmed up with either heat or soft tissue manipulation/massage. If regular stretching is also being done during the session, then Grade IV joint mobilization could be done either before or after the stretching. The ideal approach is usually to first free up intrinsic adhesions and restrictions by performing joint mobilization and then perform stretching. But as with all clinical orthopedic work, the exact approach should be determined on a case-by-case basis.

move (depress) with the humerus. Keep pressing on the humerus until shoulder girdle depression reaches the end of its motion.

2. Some traction can be added to the GH joint by pulling the humerus laterally away from the glenoid fossa with the hand that is placed on the distal humerus. This is facilitated by the placement of the thumb on the anterior surface of the elbow (Figure 9B).

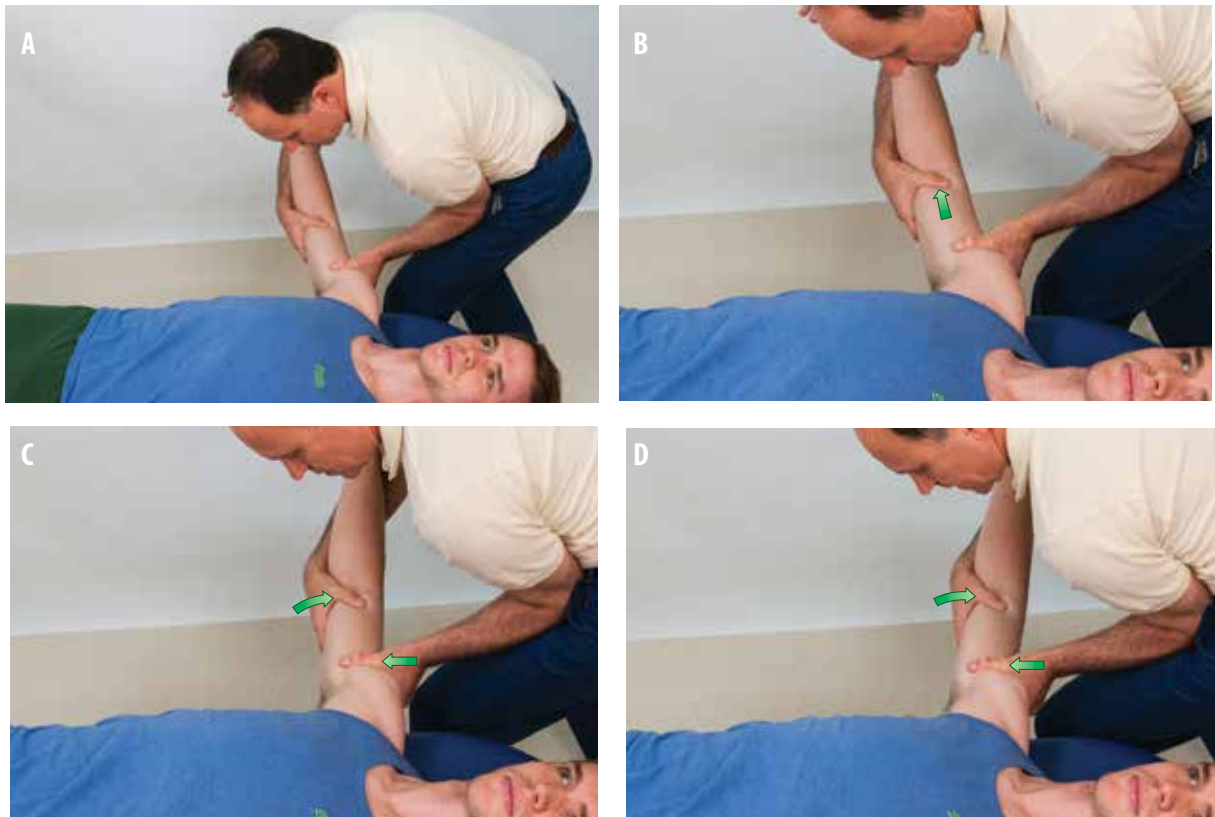
3. Challenge the humerus to roll into further abduction with the distal hand as the proximal hand glides the humerus inferiorly until tissue tension is reached (Figure 9C). (Note: As stated, the slack of scapular depression first had to be removed with this motion.)

4. Now gently add to the force with both hands, focusing primarily on the proximal hand increasing the inferior glide mobilization of the humeral head (Figure 9D). – Three to five gentle mobilization oscillations are performed, each one performed slowly with an excursion of only a few millimeters and held for only a fraction of a second.

### Example 4: Mobilization of the cervical spine:

Joint mobilization of the spine involves mobilization of the facet joints which are planar (flat), so convex/concave kinematics are not involved.

Following are the steps to perform



**FIGURE 9** Abduction with inferior glide mobilization of glenohumeral (GH) joint in the frontal plane: A, Contact the distal and proximal arm. B, Traction added. C, Further abduction with inferior glide until tissue tension is reached. D, Inferior glide mobilization of the head of the humerus. (Figure reproduced with permission from Joseph E. Muscolino)

mobilization of the C4-C5 joint into right lateral flexion.

1. Comfortably and securely place the client's head in your left hand (Figure 10A). Note: Rotating the client's head/neck to the left approximately 45 degrees helps to facilitate this protocol.
2. Contact and pin (stabilize) the right-side facet (articular process) of C5 with the radial side of the proximal phalanx of your index finger (Figure 10B). Thumb pad or finger pad contacts are also possible but are not as comfortable or strong. Note: The facets are shown in Figure

10C.

3. Bring the client's head and neck into right lateral flexion until tissue tension is reached at the end of passive range of motion of C4 on C5 (be sure to maintain your pin/stabilization contact on the facet of C5) (Figure 10D).

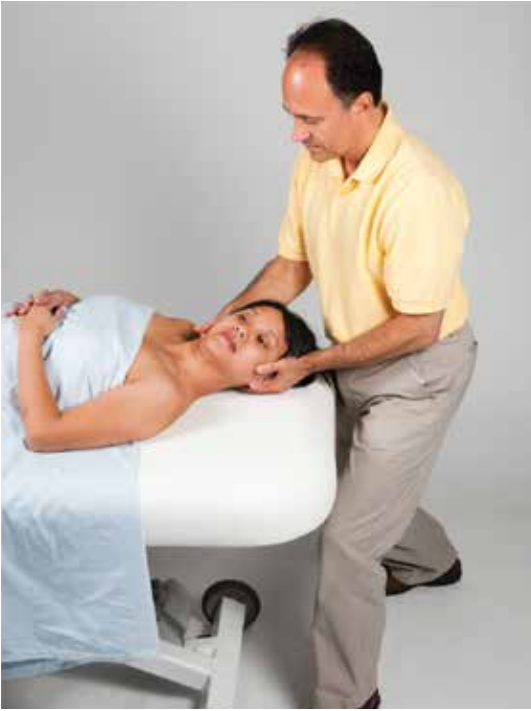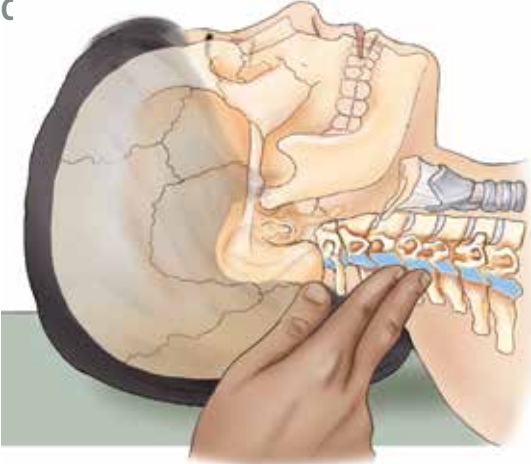
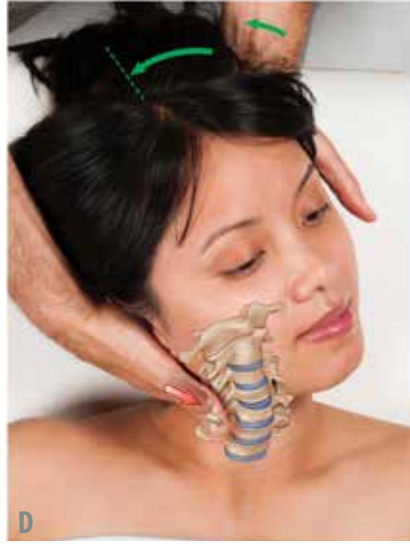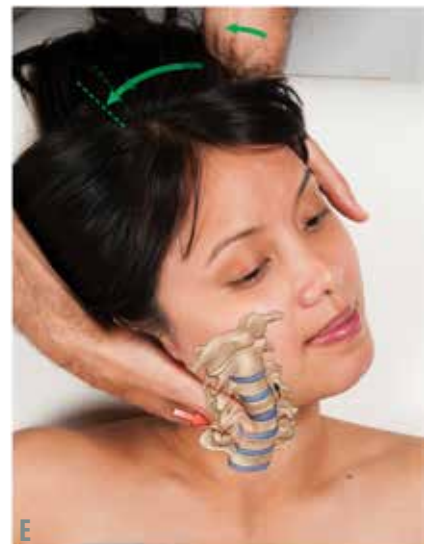4. Mobilization is performed by gently increasing the right lateral flexion of the head and neck with the left hand while the right hand contact maintains the pin on the facet of C5. This results in right lateral flexion mobilization of C4 on C5 (Figure 10E). Three to five gentle mobilization oscillations are per-

formed, each one performed slowly with an excursion of only a few millimeters and held for only a fraction of a second.

5. Note: The mobilization can also be done by instead holding the head and neck pinned with the left hand and then gently increasing the pressure against the facet of C5 to move it relative to C4. It can also be performed by moving both of your hands in concert: the left hand increases the right lateral flexion of the head (and consequently C1-C4) while the right hand presses on the facet of C5. ■

“...most massage therapists still largely ignore an incredibly important fascial tissue component of the body: joint capsules and their associated intrinsic joint ligaments. **After all, tautness in any soft tissue will decrease motion and impact the quality of the client's life.**”



**A****B****C****Lateral view****D****E**

**FIGURE 10** [clockwise] Mobilization of the cervical spine into right lateral flexion. A, Support the client's head in your left hand. Note that the client's head and neck are rotated to the left. B, Index finger contact on right-side facet of C5. C, Facets of the cervical spine are highlighted in blue. D, The head and neck are brought into right lateral flexion until tension is reached at the C4-C5 level. E, Mobilization of C4 on C5.

*Figures 10A, 10D, and 10E:* (Figure reproduced with permission from Lippincott, Williams & Wilkins, *Advanced Treatment Techniques for the Manual Therapist - Neck*, JE Muscolino) *Figures 10C:* (Figure reproduced with permission from Elsevier, *The Muscle and Bone Palpation Manual – with Trigger Points, Referral Patterns, and Stretching*, JE Muscolino) *Figures 10B:* (Figure reproduced with permission from Joseph E. Muscolino)



*Joseph E. Muscolino, DC, is a chiropractor in private practice in Stamford, CT who employs extensive soft tissue manipulation in his practice. He has been a massage educator for more than 25 years and currently teaches anatomy and physiology at Purchase College, SUNY. He is the author of multiple textbooks including The Muscle and Bone Palpation Manual, The Muscular System Manual, and Kinesiology (Elsevier) and Advanced Treatment Techniques for the Manual Therapist: Neck and Manual Therapy for the Low Back and Pelvis—A Clinical Orthopedic Approach (LWW) and the author of multiple DVDs on Manual Therapy. Joseph teaches Continuing Education Clinical Orthopedic Manual Therapy (COMT) certification workshops around the country and overseas. Visit Joseph's website at [www.learnmuscles.com](http://www.learnmuscles.com) or his professional facebook page: The Art and Science of Kinesiology.*