

NAVIGATING YOUR WAY

The Science and Art of Muscle Palpation

The importance of palpation and what it means to us as medical practitioners cannot be overly stressed. This article discusses four guidelines that primarily address the science of muscle palpation and demonstrates how mastery of this skill can be used to determine and evaluate the best course of action by the practitioner.

BY DR JOSEPH E MUSCOLINO

When treating clients presenting with a specific musculoskeletal condition, massage should never be done unless an accurate assessment has first been made. An assessment informs the practitioner about the physical integrity of the tissues of the client's body that are to be treated and points the practitioner toward the appropriate treatment tools to facilitate the healing of the condition.

Of all assessment tools available to the massage practitioner, palpation, especially palpation of the musculature, is the most important. Indeed, muscle palpation is so integral to the field of massage therapy that I believe it's likely that the massage therapy profession leads all other health fields in muscle palpation skills.

The term palpation derives from the Latin word 'palpare' - to touch.

However, in the context of muscular assessment, palpation involves much more than simply touching the muscle. Muscular palpation has two major objectives.

The first is to locate the target muscle that is being palpated and, once it has been located, the second is to assess its health by feeling for its tone and texture.

- Is it tight or loose?
- Are there trigger points located within it?
- Is it inflamed or tender to touch?
- Are fascial adhesions present?

Assessing the health of the muscle is the most important aspect of palpation because the integrity of the tissues is





what determines our decisions regarding treatment. However, if we do not first locate and discern the muscles of the region, we will not even know what musculature we are assessing. Further, effective massage therapy often involves working the entirety of the muscle, from attachment to attachment. This can only be done if we know the exact borders of the muscle.

Palpation protocols

For these reasons, accurate location of target musculature is supremely important and is the basis for clinical remedial/orthopaedic massage. Each target muscle has a palpation protocol that can be carried out to identify and locate it. At times there may be a number of possible protocols that

work equally well for a muscle.

Unfortunately, because of the manner in which it's presented in textbooks and the classroom, muscle palpation is often not well learned by students and practitioners alike.

Muscle palpation is often presented as protocols to be memorised with little understanding of why each step is done. As with most things that are memorised they are often forgotten or, in time, become fuzzy leaving us with weak palpation skills. Further, the protocols are often passed along without being critically examined thus setting the stage for massage practitioners to learn less than ideal technique.

Instead of memorising a protocol for each and every muscle, it's better to learn

how to palpate.

In other words, we need to learn an approach to muscle palpation that allows us to figure out how to palpate the muscles of the body. Further, it's important to be sure that each protocol is ideal for not only locating the target muscle but also clearly discerning it from adjacent musculature and other soft tissues. This can be accomplished with a set of guidelines that addresses the science and art of palpation.

To thoroughly cover this topic, a fairly long list could be given. However, this list can be pared down to the most important guidelines that, when followed, allow us to accurately and easily figure out how to palpate almost every muscle of the body.

These guidelines can be presented in a straightforward and commonsense manner that facilitates critical reasoning. Critical reasoning skills not only inform and improve our ability to palpate; they also inform and improve our hands-on clinical treatment technique, making us more effective clinical practitioners.

Together, these guidelines comprise the science and art of muscle palpation.

The Science of Palpation

Guideline No. 1:

Know the attachments of the target muscle

The first guideline is to know the attachments of the target muscle that is being palpated. Knowing the attachments is the first necessary step because it gives us the general location of where to place our palpating fingers.

Simply put, we palpate between the muscle's attachments.

For example, if the target muscle is the levator scapulae, knowing that it attaches from the superior angle of the scapula to the transverse processes of C1-C4, tells us to place our palpating fingers between the superior angle and the transverse process spinal attachment (Figure 1).

Hence, the first necessary step for successful palpation is knowing the attachments of the target muscle. Each muscle palpation protocol should begin, not end here as is, unfortunately, often the case.

Often, the student is taught the attachments of the target muscle and is instructed to simply palpate from attachment to attachment. Although this approach may work well when palpating the centre of a superficial muscle, once we continue to palpate that muscle toward its

borders how do we know if we have strayed off it and onto an adjacent muscle?

The problem is that this guideline does not help us discern the borders, of the target muscle from the adjacent muscles and other soft tissues.

For deeper muscles, approaching palpation just by palpating from attachment to attachment is even more problematic because we can never be sure whether we are feeling our target muscle or a more superficial muscle that overlies it.

So, important as using guideline No. 1 is, it's not sufficient for effective palpation.

Guideline No. 2:

Know the actions of the target muscle

When the target muscle contracts, it hardens and becomes palpably clearer.

Continuing with the levator scapulae as our example, if we know the muscle's actions, we know what to ask the client to do to make it contract. We ask the client to elevate her scapula at the scapulocostal joint. The levator scapulae contracts and becomes palpably harder, allowing us to palpate its entirety and more easily discern it from the adjacent musculature (Note: It is best to have the client's hand in the small of the back while doing this because this position inhibits and relaxes the upper trapezius) (Figure 2).

Guideline No. 3:

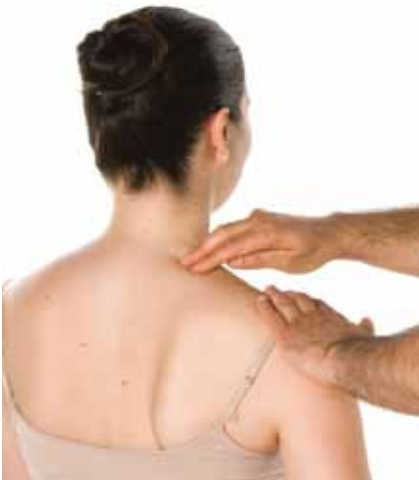Choose the best action of the target muscle to engage it

Adding contraction of the target muscle to knowing where to place our palpating fingers (guidelines No. 1 and No. 2) often creates an effective palpation protocol. However, there are many times when simply choosing any action of the target muscle will not be sufficient for a successful palpation. This is another place where some palpation protocols are less than ideal.

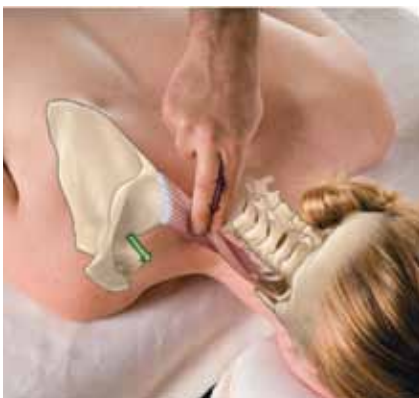The purpose of guideline No. 2 is to engage the target muscle so that it hardens and stands out from the adjacent soft tissues. However, if the chosen action also causes other muscles to engage and contract, then discerning the target muscle from these other muscles will be difficult and our palpation will not be clear.

Always keep in mind that our goal is not just to feel the target muscle; it is also to know when we are on it and when we are not.

In other words, we must clearly discern the target muscle from all other tissues. This means that we need to find an action that



Above. Figure 1



Above. Figure 2

engages the target muscle but does not engage the adjacent muscles.

In effect, we want an isolated contraction of the target muscle.

Although this is not always perfectly possible, most of the time it can be achieved quite well. Here, guideline No. 3 becomes important - choose the best action to engage the target muscle. In a sense, this guideline is a critically important refinement of guideline No. 2.

Choosing the best action to create an isolated contraction of the target muscle requires knowledge not only of the actions of the target muscle but also the actions of all the adjacent muscles. This is where our foundation of science knowledge and critical thinking skills truly become important.

What we need to do is to think through all of the actions of the target muscle to find the action that is most different from the actions of the adjacent muscles.

If for example, we are palpating the deltoid, glenohumeral abduction will engage anterior, middle and posterior fibres of the deltoid. However, if we want to palpate and discern only the anterior deltoid, flexion of the arm at the glenohumeral joint is a better joint action because it engages the anterior deltoid without also engaging the middle deltoid. In fact, an even better action for palpation of the anterior deltoid is horizontal flexion of the arm at the glenohumeral joint because it creates a more powerful contraction and engages fewer adjacent muscles (Figure 3a).

Similarly, if we want to palpate the posterior deltoid, glenohumeral joint extension is better than abduction because it engages the posterior deltoid without engaging the middle deltoid. And horizontal extension of the arm at the glenohumeral joint is the very best joint action to have the client perform because it creates the most powerful and isolated contraction of the posterior deltoid (Figure 3b).

Another example is palpation of the flexor carpi radialis (FCR) of the wrist flexor group. If we ask the client to flex the hand at the wrist joint, the FCR engages, but so will many other muscles of the anterior forearm, including the adjacent palmaris longus (PL).

This might not matter if we are palpating only the distal tendon of the FCR because it's far from the PL's distal tendon. But as we palpate more proximally onto the

FCR's belly, the belly of the PL lies directly adjacent, so it might be difficult to discern the FCR from the PL.

In this case, a better action is to have the client radially deviate (abduct) the hand at the wrist joint (Figure 4).

This action still engages the FCR but the PL remains relaxed and soft. So, when

6 ...the first necessary step for successful palpation is knowing the attachments of the target muscle. 9

palpating the FCR, guideline No. 2 only asks us to find an action that engages it. Flexion of the hand accomplishes this goal but is also a common action of other adjacent muscles. Guideline No. 3 asks us to find an action unique to the FCR amongst its adjacent musculature. In this instance, the best action is radial deviation of the hand at the wrist joint.

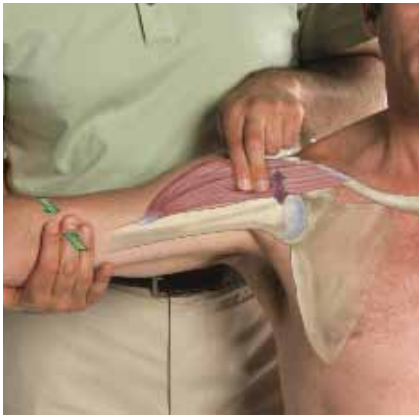Sometimes, because every one of its actions is common to at least one adjacent muscle, it's not possible to find an action that is unique to the target muscle. In these cases, choosing the best action depends upon which aspect of the target muscle we are palpating.

An excellent example is the extensor digitorum longus (EDL) of the leg (Figure 5).

The EDL extends toes two through five. However, many clients are unable to isolate toe motions, so we will use its actions of the foot instead. The EDL dorsiflexes and everts the foot. What action would be the best one to use? The answer depends upon whether we are palpating the anterior or posterior aspect of the muscle.

If we are palpating toward its anterior border next to the tibialis anterior (TA), then it's best to ask the client to evert the foot because this action engages the EDL but not the TA (The TA dorsiflexes and inverts the foot). If we had chosen dorsiflexion, both the EDL and TA would engage, making discerning the border between them difficult.

On the other hand, if we are palpating toward the EDL's posterior border, next to the fibularis longus (FL) (NB: the FL was formerly called the peroneus longus), the best action is dorsiflexion of the foot.



Above. Figure 3a.



Above. Figure 3b

Dorsiflexion engages the EDL but not the FL (the FL everts and plantarflexes the foot). If we had asked the client to evert in this case, both the EDL and the FL would have contracted, making it difficult to discern the border between them.

As you can see, the foundation of muscle palpation rests on knowing the attachments and actions of the musculature - precisely the information that we learned in our anatomy, physiology and myology/ kinesiology classes!

This manifests how science knowledge, far from being simply a burden that has to be learned for qualification or to pass school examinations, is actually very important to the hands-on skill set of massage therapy. Science informs the practice of massage therapy, raising the competence of the practitioner and allowing for effective assessment and treatment.

The most competent clinical practitioner is the one who marries the science of knowledge with the art of hands-on skills.

Guideline No. 4:
When necessary, add resistance to the client's contraction

The next step is to pay attention to how hard the client contracts the target muscle.

The reason that we ask clients to actively contract the target muscle is to make it palpably harder so it stands out among the adjacent soft tissues. This action often causes the muscle to pop out under our palpating fingers when it first contracts.

However, simply asking the client to perform the joint action does not always cause a strong enough contraction to make the target muscle easily palpable. This is especially true when the body part being moved is either not being moved upward against gravity and/or it is not heavy so that its weight does not offer enough resistance to create a strong enough contraction.

By adding resistance, the client's target muscle must contract with greater force and will palpably become even harder and easier to palpate. So, if the client contracts the target muscle and you still cannot feel it contract, add resistance.

The ideal degree of target muscle contraction can vary from muscle to muscle within the same client and from client to client for the same muscle. Be prepared to be creative with the resistance that you add.

Adding resistance to the contraction of the target muscle is where palpation

protocol errors are most often made. These errors involve placement of the practitioner's hand to contact the client when adding resistance.

For this reason, the following addendum to guideline No. 4 is helpful: when adding resistance to a client's contraction, never cross a joint that does not need to be crossed.

In short, if we are resisting the client's target muscle from moving the arm at the glenohumeral joint (such as the deltoid), we need to contact the client's distal arm, not cross the elbow joint to contact the forearm. Similarly, if the target muscle contracts to move the forearm at the elbow joint, then we should contact the client's distal forearm and not cross the wrist joint to contact the client's hand.

The problem with contacting the client across a joint that does not need to be crossed is that it causes the client to recruit and contract additional muscles. Remember, our goal is to create an isolated contraction of the target muscle so that it is the only hard tissue among a sea of soft tissues.

A good example is palpation of the brachioradialis.

The brachioradialis flexes the forearm at the elbow joint and is especially active if the forearm is in a position that is halfway between full pronation and full supination.

If we want to add resistance to its contraction, then we should contact the distal forearm and not cross the wrist joint to contact the client's hand as is so often shown in palpation protocols (Figure 6).

If, instead, we contact the hand, then muscles that radially deviate the hand at the wrist joint - such as the adjacent extensor carpi radialis longus - will contract, making it difficult to palpate and discern the brachioradialis.

An example from the lower extremity is palpation of the tensor fasciae latae (TFL).

The TFL flexes, abducts and medially rotates the thigh at the hip joint. Therefore, when adding resistance to its contraction, contact should be on the distal thigh (Figure 7).

Massage practitioners should not cross the knee joint to contact the leg. If the leg is contacted, the vastus lateralis of the quadriceps femoris group will also contract, making it difficult to discern the TFL.

Advanced techniques: coupled actions and reciprocal inhibition

Two advanced muscle palpation

guidelines are the use of coupled actions and reciprocal inhibition:

- With knowledge of coupled actions, we can engage the target muscle with an action that allows for better discernment from adjacent musculature.
- Reciprocal inhibition is a neurologic reflex that causes antagonists of a joint action to be inhibited, or relaxed. It can be used during a palpation protocol to relax musculature so that we achieve a better isolated contraction and discernment of our target muscle.

An excellent example is palpation of the brachialis. The brachialis is a flexor of the elbow joint.

However, if we ask the client to do this action, the overlying biceps brachii also contracts, blocking our ability to palpate and discern the anterior aspect of the belly of the brachialis. We can use reciprocal inhibition to relax the biceps brachii by asking the client to place the forearm in full pronation because the biceps brachii is a supinator of the forearm. Now, if we ask the client to gently flex the forearm at the elbow joint, we can palpate through the relaxed biceps brachii and feel the belly of the brachialis engage and pop (Figure 8).

Additional Guidelines

The following additional palpation guidelines primarily address the art of carrying out muscle palpation.

Look before you palpate. Very often, the target muscle can be seen to engage, especially when it's superficial. Before placing palpating fingers on the client and possibly blocking visual observation, be sure to look for the target muscle's contraction.

Find in the easiest place possible. To facilitate palpating a target muscle from attachment to attachment, try finding the muscle wherever it can most easily be palpated, and continue to palpate it from there.

Strum perpendicular. The target muscle can usually be better felt by strumming perpendicularly across it rather than palpating along its length. The 'strum' should be large enough to start on one side of the muscle/tendon, palpate onto its belly and then fall off the other side.

Follow in baby steps. To help ensure you don't veer off course when palpating the target muscle, advance along the muscle in 'baby steps', each time palpating directly adjacent to the last place you felt the muscle.

Contract and relax. When engaging the target muscle, changes in palpatory hardness are what we often feel best (in other words, when the target muscle first engages and pops). For this reason, instead of having the client hold a prolonged contraction, ask him to alternately contract and relax the target muscle; he will also find this more comfortable. Having the client contract and relax approximately once every 3 - 5 seconds works well.

Close your eyes and visualise the structures. Mindful palpation involves concentrating on your hands and not being distracted by other stimuli. Close your eyes and focus on and mentally visualise the structures under the skin that you're palpating.

Use appropriate pressure. Applying pressure that is too light is one of the most common errors made when palpating musculature, especially deeper musculature. On the other hand, using pressure that is too deep can lessen our sensitivity and be uncomfortable for the client. It is best to use whatever degree of pressure is effective and appropriate; this varies from muscle to muscle and from client to client.

Sink slowly into musculature. When palpating, move slowly for the comfort of the client and so you can process what you're feeling. Sinking slowly into musculature is especially helpful when palpating deeper musculature that requires stronger pressure.

Use the optimal palpation position. Often, there is an optimal position for the palpation of a target muscle. If the client is not in this position, ask him to change position. This is often needed if an accurate assessment is to be made.

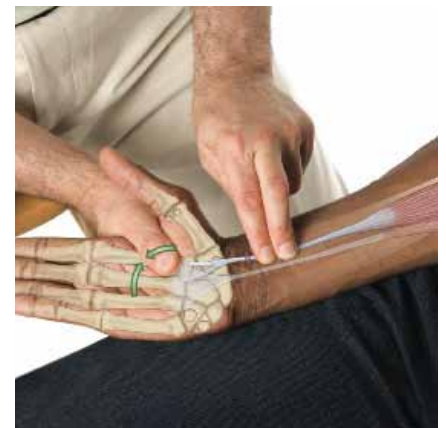Most importantly, instead of memorising a protocol for each and every muscle, it is better to learn how to palpate.

Conclusion

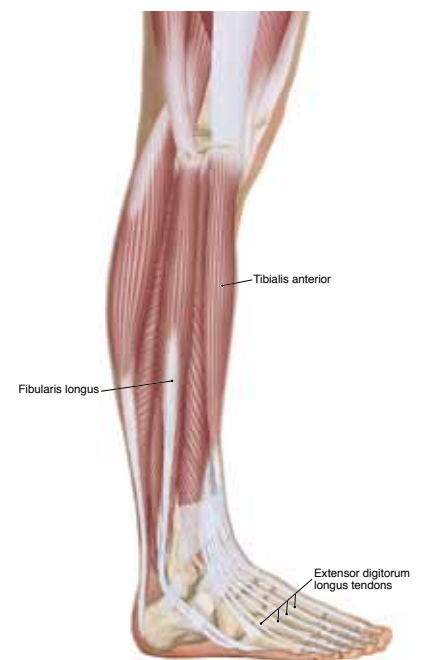
Assessment lies at the heart of remedial/orthopaedic massage and no assessment technique is more valuable to the world of massage therapy than muscular palpation.

The science of muscle palpation involves understanding and applying a set of guidelines that allows us to critically reason how to approach the muscles of the body rather than memorising rote palpation protocols.

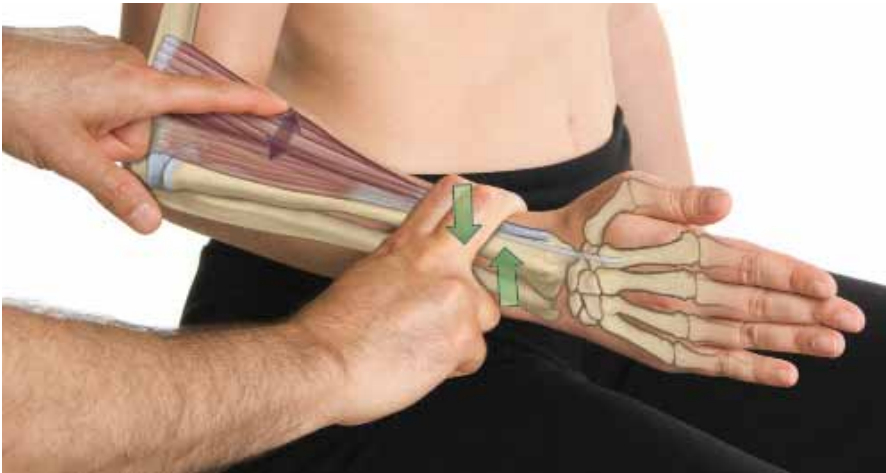The art of muscle palpation involves the quality of our touch as we seamlessly weave together these guidelines - guidelines that



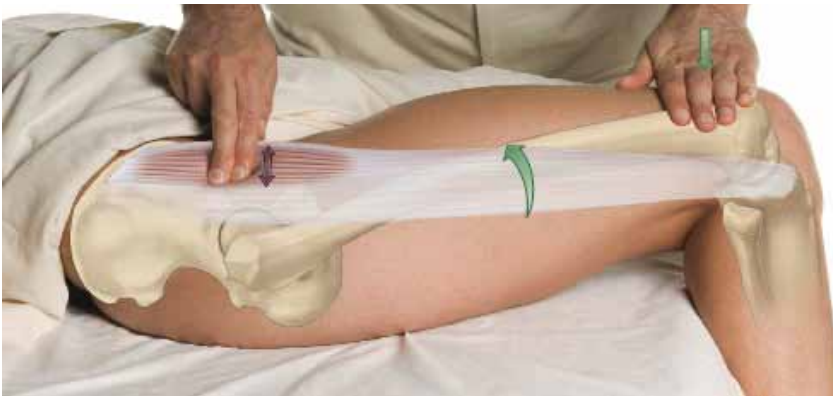Above. Figure 4.



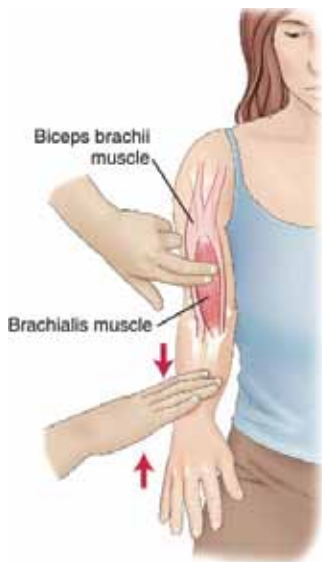
Above. Figure 5.



Above. Figure 6



Above. Figure 7



Above. Figure 8

form the foundation of palpatory literacy.

Working within these guidelines may improve not only our assessment skills but will also help us to become more effective practitioners.

About the Author

Dr. Joseph Muscolino has been a massage therapy educator for 25 years, and is owner of The Art and Science of Kinesiology, in Stamford, Connecticut in the United States. He will be visiting Australia this July to conduct a number of workshops. For more information, please visit his website (www.learnmuscles.com).

REFERENCES

Figures 10-24, 10-22A, 13-8a, 13-8b, 18-15, 14-18, 14-19a, 2-9 and 14-6: From Muscolino, JE: *The Muscle and Bone Palpation Manual, with Trigger Points, Referral Patterns, and Stretching*. St. Louis, 2009, Elsevier. Photography by Yanik Chauvin.

Figure 16-3: From Muscolino, JE: *The Muscular System Manual, The Skeletal Muscles of the Human Body*, 3ed. St. Louis, 2010, Elsevier.

Massage Therapy Journal (mtj) Quarterly publication of the American Massage Therapy Association, Vol. Winter 2010, Joseph E. Muscolino, *Effective Palpation*, Pp. 50 - 60, Copyright Massage Therapy Journal (mtj), (2010).