## WHAT IS PALPATION?

**Palpation** may be defined in many ways. The word *palpation* itself derives from the Latin palpatio, meaning "to touch." However, defining palpation as simply touching is too simplistic, because there is more involved. Inherent in the term palpation is not just touching, but also the act of sensing or perceiving what is being touched. In this sense, palpation involves more than just the fingers and hands. Palpation also involves the mind. Successful palpation requires us to feel with our minds as well as our fingers. When palpating, the therapist should be focused with a **mindful intent;** in other words, the therapist must be in his/her hands. All of the therapist's correlated knowledge of anatomy must be integrated into the sensations that the therapist's fingers are picking up from the client's body and sending to the brain. The therapist's mind must be open to the sensations that are coming in from the client, yet at the same time interpret these sensations with an informed mind (Figure 1-1). Incorporating mindful intent into examination and treatment sessions creates **mindful touch.**

### BOX 1-1

A therapist may touch and palpate the client with more than just the fingers or hands. Sometimes the forearm, elbow, or even the feet are employed to contact the client. As a rule, this text refers to fingers or hands when referring to the therapist's contact upon the client.

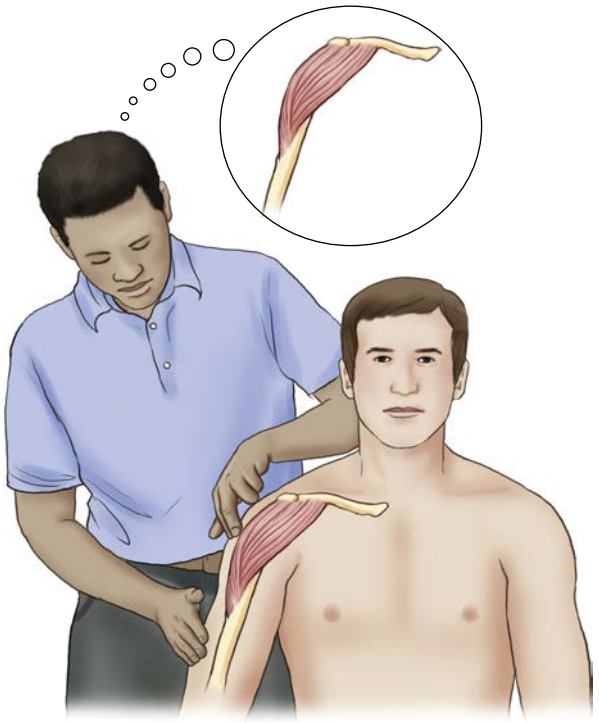

**Figure 1-1** Palpation is as much an act of the mind as it is of the palpating fingers. Sensory stimuli entering through the therapist's hands must be correlated with a knowledge base of anatomy.

## OBJECTIVES OF PALPATION: LOCATION AND ASSESSMENT

There are two main objectives when palpating. Step one is locating the target structure. Step two is assessing the target structure.

### BOX 1-2

The term **target structure** is often used to name the particular structure of the body that the therapist is targeting to palpate. If the target structure is a muscle or muscle group, it is often called the **target muscle.**

The first objective, and indeed perhaps the major objective of the novice manual therapist, is to locate the target structure being palpated. This is no easy feat to achieve. It is one thing to simply touch the tissues of the client. It is an entirely different matter to be able to touch the tissues and discern the target structure from all the adjacent tissues. This requires the therapist to be able to locate all borders of the structure, superiorly, inferiorly, medially, laterally, and even superficially and deep. If the structure is immediately superficial to the skin, this may not be very difficult. Indeed, the olecranon process of the ulna or a well-developed deltoid muscle may be visually obvious and located without even touching the client's body. However, if the target structure is deeper in the client's body, locating the structure may present a great challenge.

### BOX 1-3

As a rule, it is always best to first visually inspect the region that is to be palpated before placing your hands on the client. Once palpating hands are placed on the client, they block any visual information that might be present. See Chapter 2, The Art and Science of Muscle Palpation, for more on this idea.

As basic as palpation for the purpose of determining location seems, it is a supremely important first step, because it follows that if a structure cannot be accurately located, it cannot be accurately assessed. Once the target structure is located, then the process of assessment can begin. Assessment requires interpretation of the sensations that the palpating fingers pick up from the target structure. It involves becoming aware of the qualities of the target structure; its size, shape, and other characteristics. Is it soft? Is it swollen? Is it tense or hard? All of these factors must be considered when assessing the health of the target structure.

It is worthy of note that as high-tech diagnostic and assessment equipment continues to be developed in Western medicine, palpating hands remain the primary assessment tool of

with the target muscle, it is usually not enough to simply place our hands on the location of the target muscle and then choose any one of its actions to contract it. If the action chosen is shared with an adjacent muscle, then it will also contract, making it very difficult to discern the target muscle from the adjacent muscle.

For this reason, knowing which joint action to ask the client to perform is where the therapist needs to be creative and think critically. This is where the art of muscle palpation begins. It requires knowledge of not only of the actions of the target muscle, but also the actions of all adjacent muscles. With this knowledge, the client can be asked to perform the best joint action for the palpation of the target muscle.

**BOX 2-1**

The goal when engaging the target muscle to contract is to have an isolated contraction of the target muscle. This means that the target muscle must be the only muscle that contracts and every other muscle must remain relaxed. Although this is the ideal, it is not always possible to achieve.

**BOX 2-2**

There are times when the client is not able to perform only the action that is asked for by the therapist; this is especially true with actions of the toes, because we do not usually develop the coordination necessary to isolate certain toe motions. For example, if the target muscle is the extensor digitorum longus (EDL) and the client is asked to engage this muscle by extending toes two through five at the metatarsophalangeal and interphalangeal joints, the client may be unable to extend these toes without also extending the big toe (toe one) at the same time. This poses a problem because extending the big toe will also engage the extensor hallucis longus (EHL) muscle. When this happens, it is tempting to isolate extension of toes two through five by holding down the big toe of the client so that it does not move into extension. However, the goal of engaging the target muscle is for it to be the only muscle that contracts. If the big toe is held down in this scenario, even though the big toe is not moving, the EHL muscle is still contracting; it is simply contracting isometrically instead of concentrically. This will still cause the EHL to contract and harden, making it harder to palpate and discern the EDL. For this reason, any time that a client contracts a muscle that he or she is not supposed to, preventing the client's body part from moving does not help the palpation. It is the *contraction* of any muscle other than the target muscle that is undesirable, not the movement of a client's body part.

For example, if the flexor carpi radialis (FCR) of the wrist flexor group is the target muscle, then asking the client to flex the hand at the wrist joint will engage not only the FCR, but also the other two wrist flexor group muscles, the palmaris longus (PL) and flexor carpi ulnaris (FCU). In this case, to palpate and discern the FCR from the adjacent PL and FCU, the client should be asked to do radial deviation of the hand at the wrist joint instead of flexion of the hand at the wrist joint. This will better isolate the contraction to the FCR. It becomes palpably harder than the relaxed and palpably softer PL and FCU muscles, which facilitates palpating and locating the FCR (Figure 2-3).

## PERFECTING THE ART OF MUSCLE PALPATION

Knowing the attachments and actions of the target muscle are the first two steps of learning the science of muscle palpation. Determining which joint action to ask the client to perform is the beginning of learning the **art of muscle palpation**. However, perfecting the art of muscle palpation

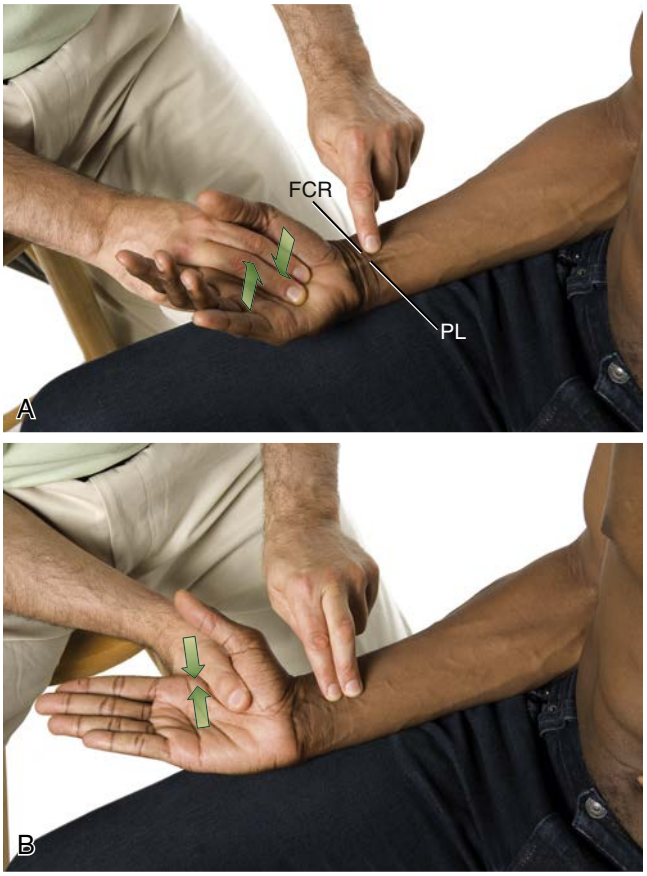


**Figure 2-3** The flexor carpi radialis (FCR) muscle is being palpated. If the client is asked to flex the hand at the wrist joint as shown in **A**, the FCR will contract, but so will the adjacent palmaris longus (PL) muscle. However, if the client is asked to radially deviate the hand at the wrist joint as shown in **B**, the contraction is isolated to the FCR while the adjacent PL remains relaxed.

involves the knowledge and application of many more guidelines. These additional guidelines are presented in the following pages. A summary list of all twenty muscle palpation guidelines has already been given. It is difficult if not impossible to memorize a list this long; rather these guidelines need to be learned by using them as the palpations of the skeletal muscles of the body are covered in Chapters 10 to 20 of Part III of this book. With practice, these guidelines will become familiar and comfortable to you and will enhance the art and science of your muscle palpation technique.

**BOX 2-3**

When palpating, the hand of the therapist that is doing the palpation is called the **palpation hand**. The other hand, in this case offering resistance, is called the **stabilization hand**.

### *Guideline #4: Add Resistance to the Contraction of the Target Muscle*

When a client is asked to do one of the joint actions of the target muscle to make it contract, harden, and stand out, there are times when this contraction is not forceful enough to make it easily palpable. This is especially true if the joint action does not require a large body part to be moved and/or if the body part that is moved is not moved against gravity. When the client's contraction of the target muscle is not forceful enough, it might be necessary for the therapist to **add resistance** so that the target muscle contracts harder and stands out more. A good example is when the target muscle is the pronator teres and the client is asked to pronate the forearm at the radioulnar joints. Because the forearm is not a very large body part and pronation does not occur against gravity, the pronator teres muscle will contract, but most likely not forcefully enough to make it stand out and be easily palpable. In this case, the therapist can add resistance to the client's contraction by resisting the forearm during pronation. This requires a more forceful contraction of the pronator teres, making it easier to palpate and discern from the adjacent musculature (Figure 2-4).

Resisting a client's target muscle contraction is not a battle between the therapist and client to see who is stronger. The role of the therapist is simply to oppose the force of the client's muscle contraction, not overpower the client. The degree that the client is asked to contract the target muscle can vary. Ideally, it should be the lightest amount necessary to bring out the target muscle's contraction so that it is palpable. This is especially true if the target muscle is a small muscle that is deep to a larger muscle that has the same action, for example, the piriformis deep to the gluteus maximus. Both of these muscles are lateral rotators of the thigh at the hip joint. As a rule, a gentle lateral rotation contraction engages the smaller deeper piriformis without engaging the larger more superficial gluteus maximus. This allows us to discern the piriformis's contraction without the gluteus maximus contracting and blocking our palpation. Ideally, we want just enough contraction to feel the piriformis "pop," in other words, to feel its contraction, while the gluteus maximus remains relaxed and soft. However, there are also times when a more forceful contraction is needed to feel a target muscle's contraction. A good guideline is to begin with a gentle resistance as you try to palpate the target muscle. If it not successful, then gradually increase the force of the resistance as necessary.

Whenever resistance is added to the contraction of the target muscle by the client, it is extremely important that the therapist does not cross any additional joints with the placement of the stabilization hand. The goal of having a

**Figure 2-4** To create a more forceful contraction of the pronator teres muscle, the therapist can hold on to the client's distal forearm and resist forearm pronation at the radioulnar joints. Note that the stabilization hand resisting the client's forearm pronation is placed on the distal forearm and does not cross the wrist joint to hold the client's hand.

**BOX 2-4**

When you ask the client to contract the target muscle or to contract it against your resistance during palpation, remember to give the client a rest every few seconds or so. Holding a sustained isometric contraction can become uncomfortable and painful. It is more comfortable for the client and actually better for our palpation procedure if the client is asked to alternately contract and relax the target muscle instead of holding a sustained isometric contraction. (See Guideline #9 for more on alternately contracting and relaxing the target muscle.)

client contract the target muscle during palpation is to limit contraction to the target muscle. This way, it will be the only muscle that is palpably hard and can be discerned from the adjacent relaxed and palpably soft muscles. However, if the therapist's stabilization hand does cross other joints, it is likely that muscles crossing these joints will also contract. This defeats the purpose of having an isolated contraction of the target muscle.

For example, in the case of the pronator teres palpation, when resistance to forearm pronation is added, it is important that the therapist's stabilization hand does not cross the wrist joint and hold the client's hand. If the stabilization hand holds the client's hand, then other muscles that cross the client's wrist joint, such as the muscles of the wrist flexor group that move the hand at the wrist joint, or flexor muscles of the fingers, will likely also contract, making it difficult to discern the pronator teres from these adjacent muscles. Therefore the resistance hand should be placed on the client's forearm (see Figure 2-4). Ideally, placing the resistance hand on the distal end of the forearm affords the best leverage force so that the therapist does not have to work as hard.

Generally, if the therapist is resisting an action of the arm at the shoulder joint, the therapist's stabilization hand should be placed just proximal to the elbow joint and not cross the elbow joint to grasp the client's forearm. If the therapist is resisting an action of the forearm at the elbow joint, the therapist's stabilization hand should be placed on the distal forearm and not cross the wrist joint to grasp the client's hand. If the therapist is resisting an action of the hand at the wrist joint, the therapist's stabilization hand should be placed on the palm of the hand and not cross the metacarpophalangeal joints to grasp the client's fingers. The same reasoning can be applied to the lower extremity and the axial body.

One other aspect of adding resistance is the angle of the client's joint when the resistance is added. As a rule, it is better to first allow the client to slightly move the joint being crossed and then contact the client to add the resistance. For example, if the muscle being palpated is a wrist flexor muscle, make sure that the client's hand is first slightly flexed at the wrist joint and then add resistance to wrist flexion (Figure 2-5). This usually creates a better isolated contraction of the target muscle, because the direction that the client must move to press against your contact is better focused at the joint where resistance is being offered. Continuing with the wrist flexor musculature again as our example, if the client is asked to contract against our resistance with the hand in neutral position at the wrist joint, it is likely that their contraction will originate at the elbow joint instead of the wrist joint, because contraction of elbow joint flexors will also push against our resistance as seen in Figure 2-5, *A*. However, if the client's hand is first slightly flexed, then the angle of the client's force cannot be generated from the elbow joint, because the line of force of elbow joint flexion


**Figure 2-5** Optimizing the angle of the client's wrist joint when offering resistance to flexion is important. **A**, The wrist joint is in neutral position. **B**, The wrist joint is first slightly flexed.

**TABLE 3-1 Draping Techniques—cont'd**

| Position | Description |
|---|---|
| Side lying lower extremity (that is closer to the table) | To access the lower extremity that is next to the table of a side lying client, undrape the area, gather the fabric, and then tuck the sheet around the upper part of the thigh. The knee joint is slightly flexed. A rolled-up towel can be placed under the ankle for client comfort. Note that the other lower extremity remains draped and supported by a draped cushion (Figure 3-11). |

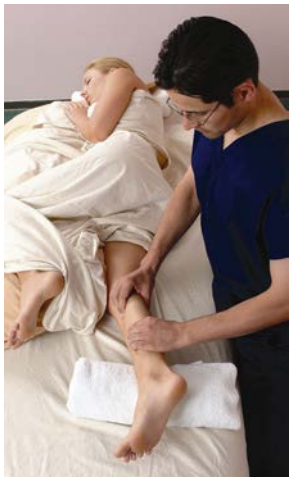

Figure 3-11

## MASSAGE STROKES

### *Introduction to Massage Strokes*

Massage application involves touching the body to manipulate soft tissues, influence body fluid movement, and stimulate neuroendocrine responses. During a massage session, many different strokes are often employed. However, more fundamental than the strokes themselves are the characteristics of the touch of the strokes. Following is the classification of massage by pioneer Gertrude Beard, as well as current trends in therapeutic massage.

The touch of a massage stroke can be characterized by the following seven characteristics: depth of pressure, drag, direction, speed, rhythm, frequency, and duration. Each of these seven characteristics is described. Following their description, a compendium of the major treatment strokes employed in massage therapy is presented with a brief description and illustration of each stroke.

## CHARACTERISTICS OF TOUCH

### *Depth of Pressure*

**Depth of pressure**, or the compressive force of massage, can be light, moderate, or deep.

Most areas of the body consist of four major tissue layers. These layers are the skin, superficial fascia, layers of musculature, and various fascial sheaths. Soft tissue dysfunction can develop in any or all of these layers. When dysfunction is present more superficially, the depth of pressure necessary is usually light. When dysfunction is present in deeper layers, deeper pressure is usually necessary. Pressure should be delivered through each successive layer, reaching deeper layers without damage and discomfort to superficial tissues. As a rule, the deeper the pressure, the broader the base of contact required on the body's surface, and the more slowly the therapist should sink into the client's tissues. To treat any soft tissue dysfunction, such as a trigger point or spasm, the therapist applies the proper level of pressure to reach the location of the dysfunction. It should be noted that pressure, by virtue of compressing tissues, also alters the circulation of fluids within the body.

### *Drag*

**Drag** describes the amount of pull (stretch) on the tissue. Drag is a component of connective tissue massage wherein one layer of tissue is dragged/pulled along an adjacent layer, helping to break up patterns of adhesions. Drag is also used during palpation assessment of various soft tissue dysfunctions to identify areas of ease and bind within the tissues. *Ease* occurs when tissue moves freely and easily; *bind* occurs when tissue feel stuck, leathery, or thick.

### *Direction*

**Direction** can move out from the center of the body (centrifugal) or in from the extremities toward the center of the body (centripetal). Furthermore, direction can proceed longitudinally, along a muscle following the direction of its fibers; transversely, across the direction of the fibers; or circularly. Direction is a factor in broadening and lengthening tissues containing soft tissue dysfunctions or in the methods that influence blood and lymphatic fluid movement.

### *Speed*

**Speed** is the rate that massage methods are applied. The speed of a stroke can be fast, slow, or variable, depending upon the demands of the tissues being addressed and the state of the client (faster and more energizing in situations where stimulation is called for, slower and more rhythmic where calming influences are needed).

### *Rhythm*

**Rhythm** refers to the regularity of technique application. If the method is applied at regular intervals, it is considered even, or rhythmic. If the method is disjointed or irregular,

it is considered uneven, or arrhythmic. Rhythmic stroking tends to be more calming, especially if applied slowly and with mild to moderate pressure. Arrhythmic strokes, especially arrhythmic jostling and shaking, tend to be more stimulating.

### Frequency

**Frequency** is the number of times that a treatment method is repeated in a given time frame. This aspect relates to how many repetitions of a stroke, such as a compression or gliding stroke, are performed. In general, the massage practitioner repeats each stroke three to five times before moving or switching to a different one. Although every application of a stroke is therapeutic, the therapist should also be assessing the health of the client's tissues as they are treated with the strokes. If the final stroke indicates remaining dysfunction, then the frequency can be increased and more strokes performed on that tissue.

### Duration

**Duration** has two aspects. It can mean the length of time the session lasts or the length of time that a particular stroke or other treatment application, such as a stretch, is used in the same location. Typically, duration of a specific stroke application is approximately 30 to 60 seconds. Certain treatment protocols may call for less or more time.

## COMPENDIUM OF MASSAGE STROKES

Following is a description of the six major types of massage therapy strokes: gliding, kneading, friction, compression, percussion, and vibration.

### Gliding

A **gliding** stroke (historically known as **effleurage**) is a long, broad stroke that is usually applied along the direction of the muscle fibers. It can also be applied across the muscle fibers; when this is done, it is often called *stroking*.

In this example of gliding (Figure 3-12), the therapist starts at the top of the client's back and applies pressure using the palms of her hands on both sides of the spinous processes until she arrives at the sacrum. The hands then separate and slide back toward the top of the back using just the weight of the hands. Contact with the client's skin is maintained when moving from pushing to pulling and between repetitions.

In Figure 3-13, the client is supine with her head and neck rotated to one side. Pressure is applied with the fist from the occiput to the acromion process and then back to the occiput. While on the cervical vertebrae, the pressure is focused over the laminar groove. While on the top of the shoulder, the pressure is focused on the thickest portion of the upper trapezius.

### Kneading

A **kneading** stroke (historically known as **petrissage**) lifts the tissue, and then the full hand is used to squeeze the tissue as it rolls out of the hand, while the other hand prepares to lift additional tissue and repeat the process. Skin rolling is a variation of a kneading stroke.

The therapist positions herself between the supine client's head and shoulder; this helps keep her wrist joint as straight as possible. The upper trapezius is compressed, lifted, and then released (Figure 3-14).


**Figure 3-12** Gliding example #1: Long stroke gliding along the back.

**Figure 3-13** Gliding example #2: Gliding along the neck and shoulder.

In Figure 3-15, the client is lying supine while the therapist kneads the client's left thigh. The hands move in opposite directions; one hand applying a force forward while the other is pulling back. The tissue under the therapist's hands is compressed, twisted, and squeezed. The hands cross each other midstroke.

### Compression

A **compression** stroke directs pressure downward into the tissues at a 90-degree angle to the contour of the surface of the body part being worked (Figure 3-16). A compression stroke spreads or displaces surface layers of tissues. It is often applied with a "pumping" action in which the pressure is gradually increased as the compression is applied.


**Figure 4-4** Demonstration of the importance of the orientation and alignment of the therapist's core (trunk and pelvis). **A** illustrates a long massage stroke along the spine on the paraspinal musculature. **B** and **C** illustrate core alignment during the application of force to a client's neck with the therapist working from a seated position. In **B,** the therapist is working the client's lower neck. In **C,** the therapist is working the client's upper neck.

being) inside the anterior superior iliac spine (ASIS). When the therapist now leans in with his core, his body weight is transmitted right through his forearm and hand into the client.

Note: When aligning the core of the body longitudinally up the table as seen in Figure 4-4, *A*, it is important to rotate the pelvis from the hip joints and not to rotate the spine. The positioning of your feet is also important and is addressed in the next guideline.

### *Guideline #5: Position the Feet*

Thus far, much has been said about the importance of the positioning, orientation, and alignment of your core. However, there is an old adage in sports that says, "It's all in the

**BOX 4-8**

Aligning the core along the direction of force is largely a matter of proper positioning of the feet. This is discussed in more detail in Guideline #5.

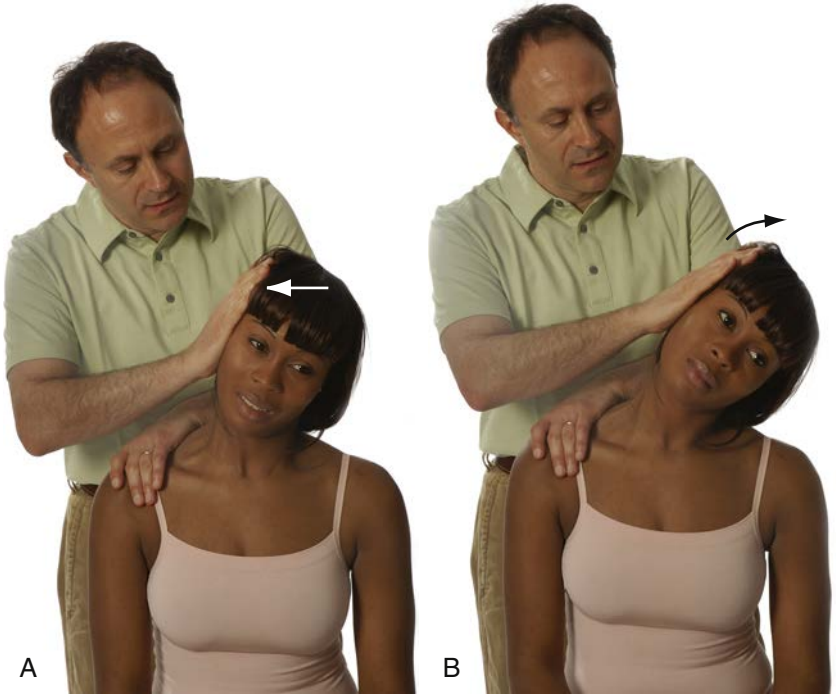


**Figure 6-8** Contract relax (CR) stretching of the right lateral flexor musculature of the neck and head is shown. In **A,** the client is isometrically contracting the right lateral flexor musculature against resistance provided by the therapist. In **B,** the therapist is now stretching the right lateral flexor musculature by moving the client's neck and head into left lateral flexion. (From Muscolino JE: Stretch your way to better health, Massage Ther J 45[3]:167-171, 2006. Photos by Yanik Chauvin.)


**Figure 6-9** Agonist contract (AC) stretching for the right lateral flexor musculature of the neck is shown. **A** shows the client actively performing left lateral flexion of the neck. **B** shows that at the end of range of motion of left lateral flexion, the therapist then stretches the client's neck further into left lateral flexion. (Modified from Muscolino JE: Stretch your way to better health, Massage Ther J 45[3]:167-171, 2006. Photos by Yanik Chauvin.)

**Superior Border of the Scapula**. The **superior border of the scapula** is more challenging to palpate than the medial and lateral borders. First, trace the medial border of the scapula up to the superior angle once again. Once the superior angle has been located, continue to palpate laterally along the superior border with your pressure directed inferiorly against the superior border (Figure 7-15). Elevating the scapula (at the scapulocostal joint) may help to bring out the superior border a bit more. Palpating the entire length of the superior border of the scapula is usually not possible.

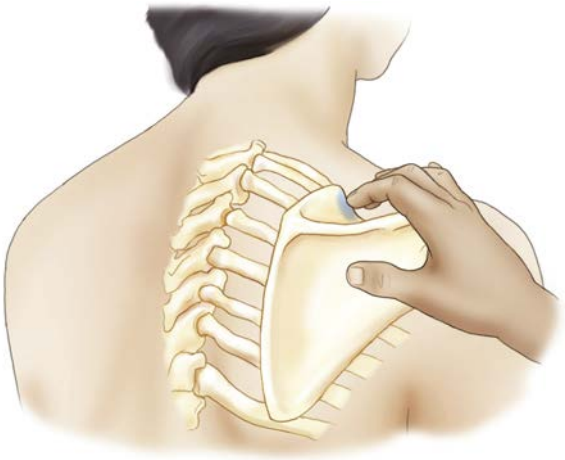

Posterolateral view

**Figure 7-15** Superior border of the scapula.

PLEASE NOTE: The omohyoid muscle attaches to the superior border of the scapula. The levator scapulae muscle also attaches onto the superior border of the scapula at the superior angle.

**Subscapular Fossa of the Scapula**. The **subscapular fossa** is located on the anterior surface of the scapula and can be slightly challenging to palpate. With the client supine, grasp the medial border of the client's scapula with one hand and passively protract the scapula. With your other hand, palpate slowly but firmly against the anterior surface of the scapula (Figure 7-16).

Lateral view

**Figure 7-16** Subscapular fossa of the scapula.

PLEASE NOTE: The subscapularis muscle attaches to the subscapular fossa on the anterior side of the scapula; the serratus anterior muscle also attaches to the anterior side of the scapula, along the medial border.

7

## SECTION 2: ARM AND FOREARM

**Greater Tubercle, Bicipital Groove, and Lesser Tubercle of the Humerus**. The **greater tubercle** is located on the lateral side of the **bicipital groove**; the **lesser tubercle** is located on the medial side. First locate the anterolateral margin of the acromion process of the scapula and then drop immediately off it onto the head of the humerus; you should be on the greater tubercle of the humerus. Figure 7-17, *A*, is an anterolateral view of the proximal arm; Figure 7-17, *B*, is a superior view looking down the arm in which we see the contours of the greater and lesser tubercles and the bicipital groove between. Now, with a flat finger pad palpation across the anterior surface of the head of the humerus, passively move the client's arm into lateral rotation at the shoulder joint. You should be able to feel your palpating finger dropping into the bicipital groove as it passes under your finger pads (see Figure 7-17, *C*). As you continue to passively move the client's arm into lateral rotation, you will feel the lesser tubercle under your fingers, just medial to the bicipital groove (see Figure 7-17, *D*). If you do not successfully feel the tubercles and bicipital groove,

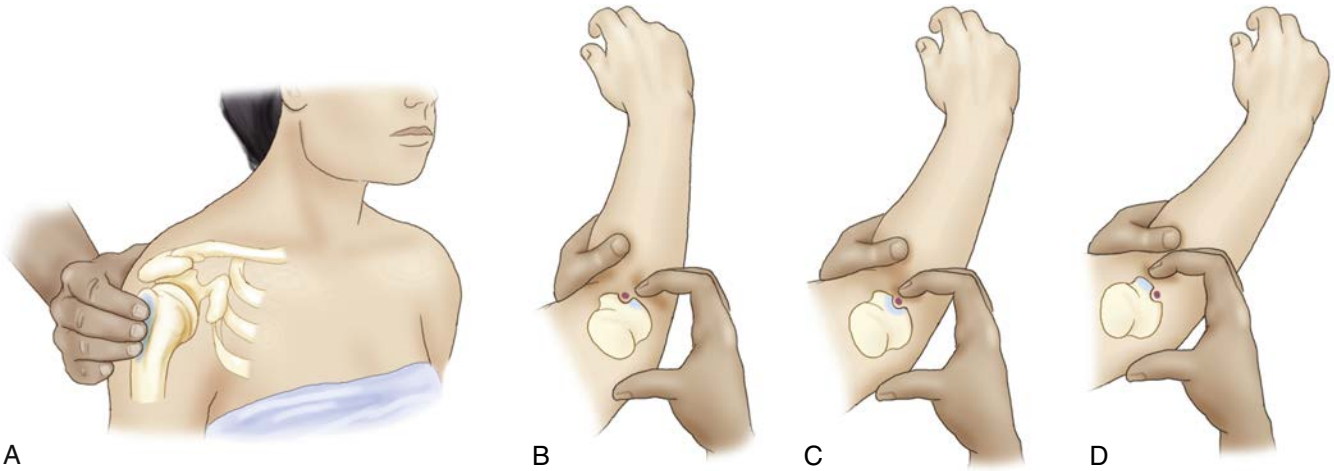


Anterolateral view Superior view

**Figure 7-17** Greater tubercle, bicipital groove, and lesser tubercle of the humerus.

alternately move the client's arm through medial and lateral rotation, feeling for them.

PLEASE NOTE: The long head of the biceps brachii muscle runs through the bicipital groove; the supraspinatus, infraspinatus, and teres minor muscles attach onto the greater tubercle; the subscapularis muscle attaches onto the lesser tubercle.

**Deltoid Tuberosity**. From the tubercles on the head of the humerus, move distally down the lateral surface of the shaft of the humerus until you feel a bony prominence approximately ⅓ of the way down the lateral surface of the shaft of the humerus. This is the **deltoid tuberosity** (Figure 7-18). This landmark can often be located by following the deltoid muscle distally to its attachment into the deltoid tuberosity.

PLEASE NOTE: The deltoid attaches to the deltoid tuberosity of the humerus. Also attaching very close to the deltoid tuberosity is the proximal attachment of the brachialis.



**Medial and Lateral Epicondyles of the Humerus**. To locate the **medial and lateral epicondyles of the humerus**, ask the client to flex the forearm at the elbow joint to approximately 90 degrees; place your palpating fingers (thumb and middle finger) on the medial and lateral sides of the client's arm (Figure 7-19, *A*). Now move distally down the client's arm with your palpating fingers, and you will clearly run into the medial and lateral epicondyles of the humerus (see Figure 7-19, *B*). They are prominently the widest points along the sides of the humerus near the elbow joint.

Lateral view

**Figure 7-18** Deltoid tuberosity.

PLEASE NOTE: Five muscles attach onto the medial epicondyle of the humerus: pronator teres, flexor carpi radialis, palmaris longus, flexor carpi ulnaris, and flexor digitorum superficialis; the flexor pollicis longus also usually attaches onto the medial epicondyle. Six muscles attach to the lateral epicondyle of the humerus: the extensor carpi radialis brevis, extensor digitorum, extensor digiti minimi, extensor carpi ulnaris, anconeus, and supinator.

**Olecranon Process of the Ulna**. The **olecranon process of the ulna** is extremely easy to locate. With the thumb and middle finger on the medial and lateral epicondyles of the humerus, place your index finger on the point of the elbow (the olecranon process), located halfway between the two epicondyles (Figure 7-20). Note: If the client's elbow joint is flexed, the olecranon process will be located farther distally than the two epicondyles of the humerus. Be careful with palpatory pressure between the medial epicondyle of the humerus and the olecranon process of the ulna due to the presence of the ulnar nerve, which is known in lay terms as the "funny bone."

PLEASE NOTE: The triceps brachii and anconeus muscles attach onto the olecranon process.

**Olecranon Fossa of the Humerus**. Once the olecranon process of the ulna has been located, the **olecranon fossa of the humerus** is fairly easy to locate. The client's forearm must be partially flexed at the elbow joint so that the olecranon fossa of the humerus is exposed (in full extension, the olecranon process of the ulna is located in and obstructs palpation of the olecranon fossa of the humerus). Find the most proximal midline point of the olecranon process of the ulna and drop off it just proximally, and you will feel the olecranon fossa of the humerus (Figure 7-21).

PLEASE NOTE: The distal tendon of the triceps brachii muscle overlies the olecranon fossa of the humerus.

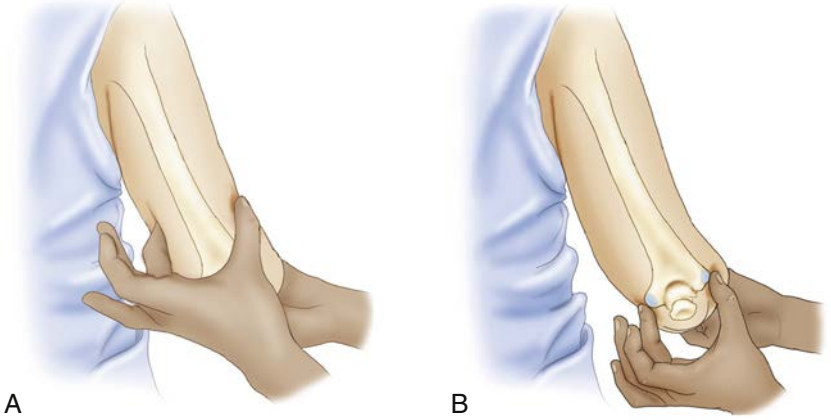


Posterior view

**Figure 7-19** Medial and lateral epicondyles of the humerus.

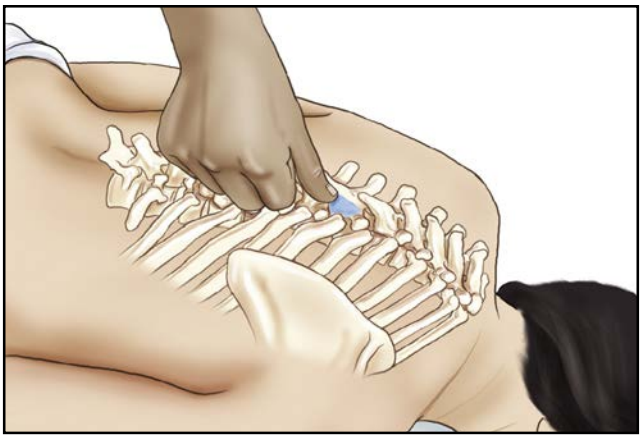

Posterolateral view

**Figure 8-29** Laminar groove of the trunk.

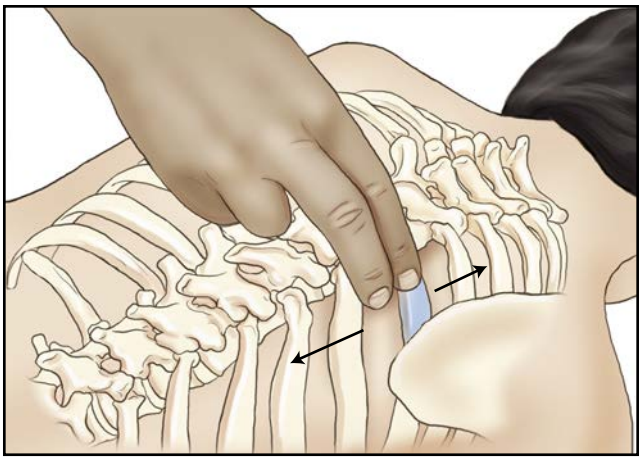

Posterolateral view

**Figure 8-30** Posterior rib cage.



**Laminar Groove of the Trunk.** The laminar groove of the thoracic and lumbar regions is the groove that is found between the SPs medially and the TPs laterally (i.e., the laminar groove overlies the laminae of the vertebrae). Palpate just lateral to the SPs and you will be in the laminar groove (Figure 8-29).

PLEASE NOTE: The transversospinalis group attaches into the laminar groove of the trunk. Many other muscles overlie the laminar groove.

**Posterior Rib Cage.** The ribs and intercostal spaces of the rib cage can be palpated in the posterior trunk in the **interscapular region** (between the scapulae) of the upper thoracic spine and in the region of the lower thoracic spine as well. Begin palpating in the interscapular region of the posterior trunk by vertically strumming across the ribs (up and down). Once you have gotten the feel of the ribs and intercostal spaces in this region, palpate each rib by simultaneously placing one finger pad on it and another finger pad on the adjacent intercostal space (Figure 8-30). Palpate all twelve ribs (at, above, and below your starting point) in this manner. Depending upon the musculature of the client, it may be easy or somewhat difficult to discern all the ribs. Where the scapulae are not in the way, follow the ribs and intercostal spaces as far lateral as possible.

PLEASE NOTE: The following muscles attach onto the rib cage posteriorly: the latissimus dorsi, serratus posterior superior, serratus posterior inferior, erector spinae group, quadratus lumborum, levatores costarum, external intercostals, and internal intercostals. The subcostales and the diaphragm attach to the internal side of the posterior rib cage. Although primarily anterior, the external abdominal oblique, internal abdominal oblique, and transversus abdominis are located somewhat posteriorly on the rib cage as well.

## SECTION 7: LIGAMENTS OF THE AXIAL BODY

Ligaments are fibrous fascial tissue that connects bones at a joint. The function of a ligament is to maintain stability of a joint by limiting motion. Figure 8-31 is an anterior view of the ligaments of the axial skeleton. One vertebral body has been removed. Figure 8-32 is a posterior view of the ligaments of the axial skeleton. Note: The posterior atlanto-occipital membrane is the superior continuation of the ligamentum flavum. Figure 8-33 is a posterior view of the ligaments of the upper cervical region. The atlas and axis have been cut. Notes: 1) The posterior atlanto-occipital membrane is the superior continuation of the ligamentum flavum. 2) The tectorial membrane is the superior continuation of the posterior longitudinal ligament. 3) The occiput has been cut on the right side to expose the tectorial membrane. 4) The tectorial membrane has been cut to expose the cruciate ligament of the dens, alar, and accessory atlantoaxial ligaments. And Figure 8-34 depicts right lateral views of the ligaments of the spine. Figure 8-34, *A*, is a sagittal section that shows the ligaments of the cervical spine. Note: The tectorial membrane is the superior continuation of the posterior longitudinal ligament. Figure 8-34, *B*, shows ligaments of the thoracic spine. The ribs have been cut; one rib has been entirely removed to show the TP attachment of a superior costotransverse ligament; the facets for the rib are also seen. Figure 8-34, *C*, shows the ligaments of the lumbar spine.

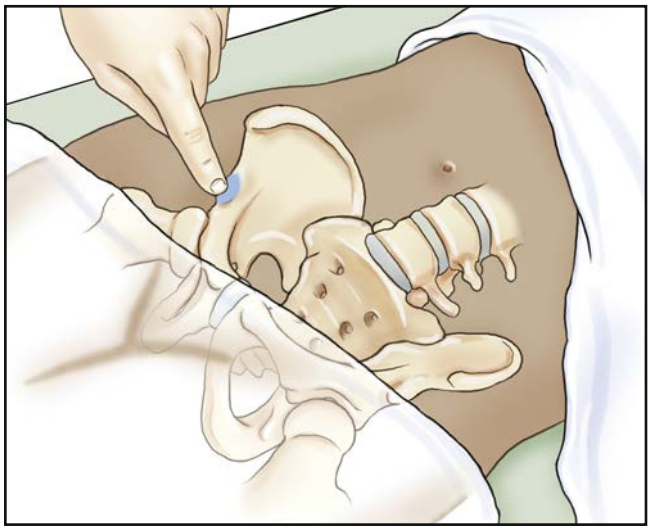

Inferolateral view

**Figure 9-10** Anterior inferior iliac spine (AIIS).

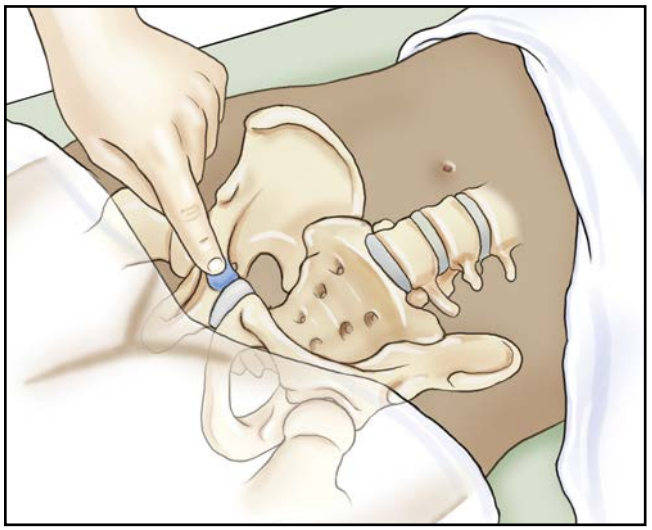

Inferolateral view

**Figure 9-11** Pubic bone and pubic tubercle.

## SECTION 2: THIGH AND LEG

### *Distal View of the Proximal Anterior Thigh (Figure 9-12)*

**Greater Trochanter.** Begin palpation of the thigh by locating again the greater trochanter of the femur. The greater trochanter is located in the proximal lateral thigh, at approximately the same level as the public tubercle. It is fairly large (approximately 1.5 × 1.5 inches [4 × 4 cm]) and subcutaneous, hence it is fairly easy to palpate; strum along it vertically and horizontally to feel the entire greater trochanter (Figure 9-13).

PLEASE NOTE: The following muscles attach onto the greater trochanter: the gluteus medius, gluteus minimus, piriformis, superior gemellus, obturator internus, inferior gemellus, and vastus lateralis.

**Lesser Trochanter.** The **lesser trochanter of the femur** is located in the proximal medial thigh. It is a palpable landmark, but is appreciably more challenging to discern, so palpating it with certainty requires more advanced palpation skills and

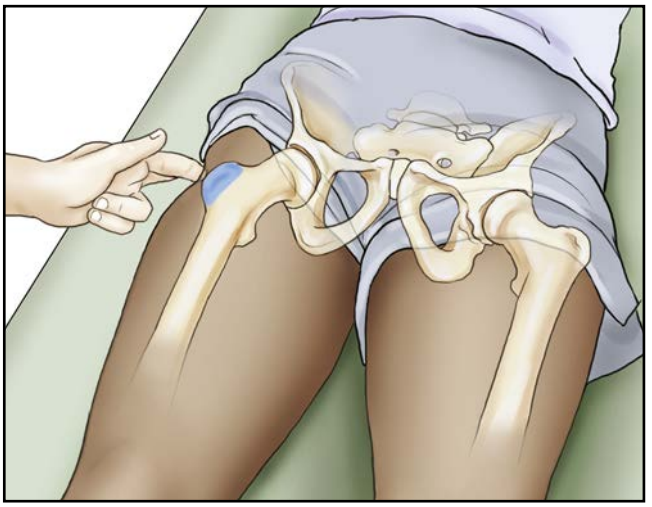

Distal view

**Figure 9-13** Greater trochanter.

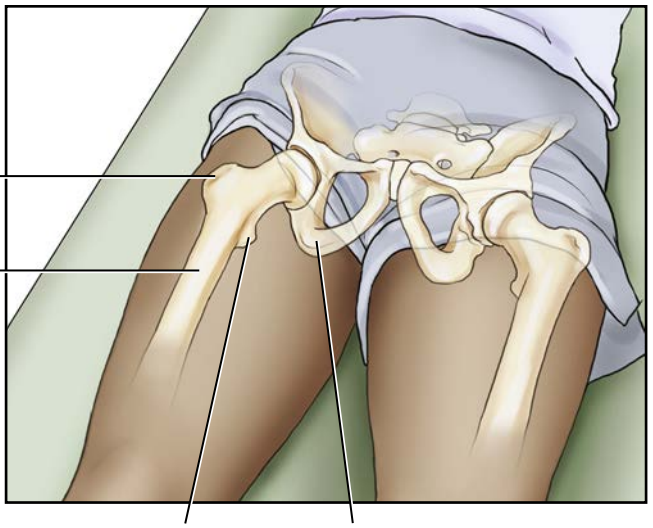


Distal view

**Figure 9-12** Distal view of the proximal anterior thigh.

knowledge of the psoas major muscle. To locate the lesser trochanter of the femur, the distal aspect of the psoas major muscle must be located. Once located, follow the psoas major distally as far as possible. Then have the client relax their thigh in a position of flexion and lateral rotation of the thigh at the hip joint to relax and slacken the psoas major; then press in against the femur, feeling for the lesser trochanter (Figure 9-14).

PLEASE NOTE: The psoas major and iliacus muscles (iliopsoas muscle) attach onto the lesser trochanter.

**Patella.** The **patella** (kneecap) is a prominent sesamoid bone located anterior to the distal femur. To best palpate the patella, have the client supine with the lower extremity relaxed (Figure 9-15). Palpate the entire patella, gently gliding along the patella horizontally and vertically.

PLEASE NOTE: The quadriceps femoris group attaches onto the patella.

### *Anterolateral View of the Leg with the Knee Joint Flexed to 90 Degrees (Figure 9-16)*

**Trochlear Groove of the Femur.** To palpate the **trochlear groove of the femur**, the knee joint should be flexed approximately 90 degrees and the quadriceps femoris musculature relaxed. (When the knee joint is fully extended, the patella moves proximally within the trochlear groove and obstructs its palpation.) Now palpate immediately proximal to the patella in the midline of the anterior femur, and the trochlear groove

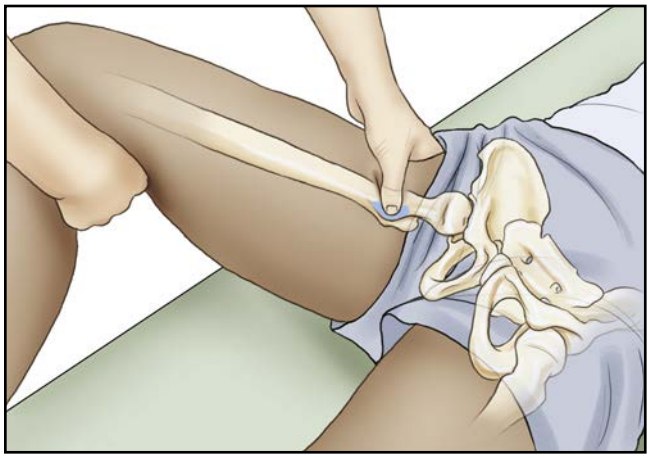

**Distal and medial view**

**Figure 9-14** Lesser trochanter.

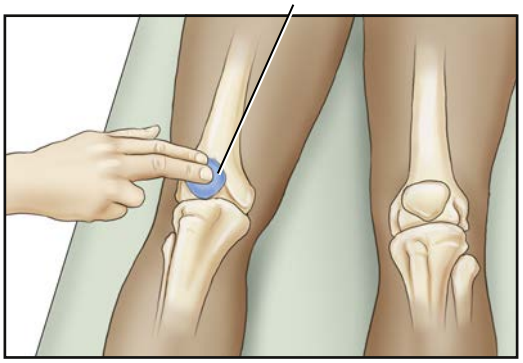


**Distal and anterior view**

**Figure 9-15** Patella.

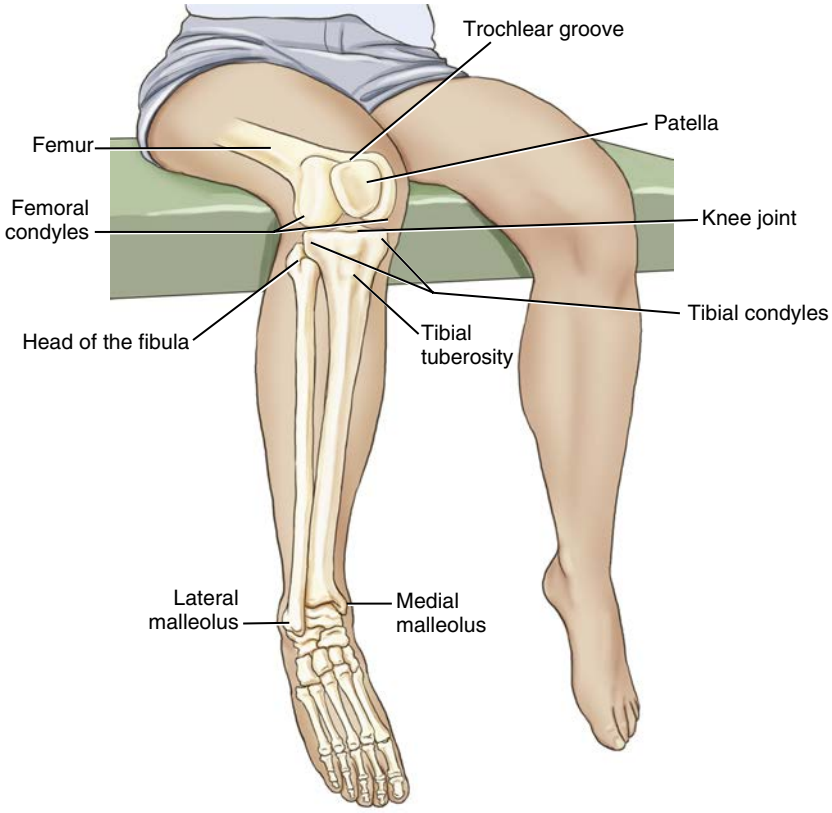


**Anterolateral view**

**Figure 9-16** Anterolateral view of the leg with the knee joint flexed to 90 degrees.

## TRAPEZIUS—PRONE

### ATTACHMENTS

- ☐ External occipital protuberance, medial ⅓ of the superior nuchal line, nuchal ligament, and the spinous processes of C7 through T12

*to the*

- ☐ lateral ⅓ of the clavicle, acromion process, and spine of the scapula

### ACTIONS

#### Upper Trapezius

- ☐ Elevates the scapula at the scapulocostal (ScC) joint
- ☐ Retracts the scapula at the ScC joint
- ☐ Upwardly rotates the scapula at the ScC joint
- ☐ Extends the head and neck at the spinal joints
- ☐ Laterally flexes the head and neck at the spinal joints
- ☐ Contralaterally rotates the head and neck at the spinal joints

#### Middle Trapezius

- ☐ Retracts the scapula at the ScC joint

#### Lower Trapezius

- ☐ Depresses the scapula at the ScC joint
- ☐ Retracts the scapula at the ScC joint
- ☐ Upwardly rotates the scapula at the ScC joint

### Starting Position (Figure 10-7)

- Client prone with arm resting on the table at the side of the body
- Therapist standing to the side of the client
- Palpating hand placed just lateral to the lower thoracic spine (on the lower trapezius)

### Palpation Steps

1. Ask the client to abduct the arm at the glenohumeral (GH) joint to 90 degrees with the elbow joint extended, and to slightly retract the scapula at the ScC joint by pinching the shoulder blade toward the spine (Figure 10-8). Adding gentle resistance to the client's arm abduction with your support hand might be helpful.
2. Palpate the lower trapezius. To locate the lateral border, palpate perpendicular to it (Figure 10-9, *A*). Once located, palpate the entire lower trapezius.
3. Repeat for the middle trapezius between the scapula and the spine. Strum perpendicular to the direction of the fibers (i.e., strum vertically) (see Figure 10-9, *B*).
4. Repeat for the upper trapezius.
5. To further engage the upper trapezius, ask the client to do slight extension of the head and neck at the spinal joints. Then palpate the entire upper trapezius (see Figure 10-9, *C*).
6. Once the trapezius has been located, have the client relax it and palpate to assess its baseline tone.

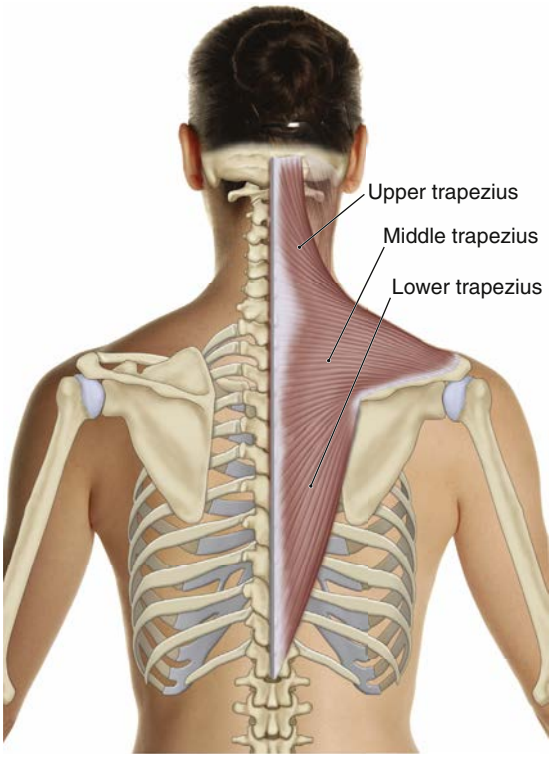


**Figure 10-6** Posterior view of the right trapezius. The sternocleidomastoid (SCM), levator scapulae, and splenius capitis are ghosted in.

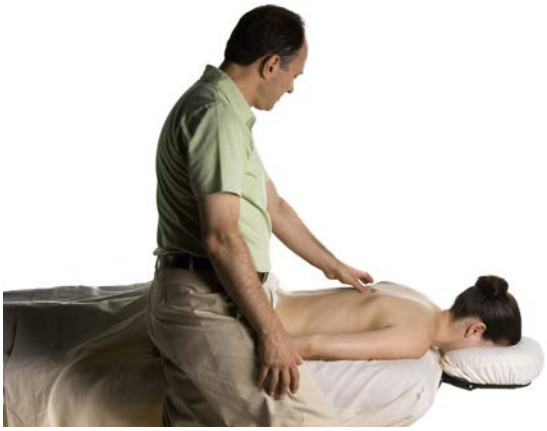

**Figure 10-7** Starting position for prone palpation of the right trapezius.

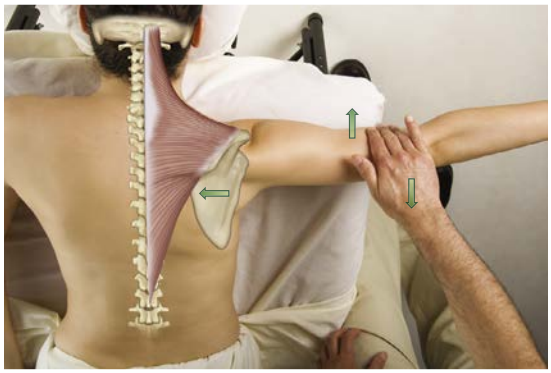

**Figure 10-8** To engage the entire right trapezius, the client abducts the arm at the glenohumeral (GH) joint (resistance can be added as shown) and slightly retracts the scapula at the scapulocostal (ScC) joint.

## TRAPEZIUS—PRONE—*cont'd*


**Figure 10-9** Palpation of the right trapezius. **A** shows palpation of the lower trapezius. **B** shows palpation of the middle trapezius. **C** shows palpation of the upper trapezius. Palpation of the upper trapezius is facilitated by asking the client to slightly extend the head and neck at the spinal joints. For all three parts of the trapezius, palpate while strumming perpendicular to the fiber direction as shown.



### PALPATION NOTES

1. Abducting the arm at the glenohumeral (GH) joint requires an upward rotation force by the upper and lower trapezius to first stabilize the scapula and then move the scapula into upward rotation. Retracting the scapula engages the entire trapezius, especially the middle trapezius.
2. Clients often lift the arm up into the air when asked to retract the scapula. Emphasize that the client should "pinch the shoulder blade back." However, the client should not retract the scapula excessively, or the scapula moves too close to the spine, and the retractor musculature in the interscapular region bunches up, making it difficult to palpate the middle trapezius.
3. When asking the client to extend the head and neck to further engage the upper trapezius, do not have the client extend very far or it will be difficult to palpate into the neck.
4. The lateral border of the lower trapezius is often visible; look for it before placing your palpating hands on the client.

### Palpation Key:

Fly like an airplane:
If both trapezius muscles are palpated at the same time, both arms out to the sides make the client appear to be flying like an airplane.

## TRAPEZIUS—PRONE—*cont'd*

### TRIGGER POINTS

1. Trigger points (TrPs) in the upper trapezius often result from or are perpetuated by acute or chronic overuse of the muscle. Examples include chronic postures of elevation of the shoulder girdle; anteriorly held head; any chronic posture due to poor ergonomics, especially while sitting at the computer or crimping the phone between the shoulder and ear; resisting depression of the shoulder girdle when the upper extremity is hanging, especially when the upper extremity is carrying a weight; trauma (e.g., whiplash); compression forces (e.g., carrying a heavy purse or backpack on the shoulder, having a tight bra strap); or chronic stress/tension (holding the shoulder girdles uptight). Middle trapezius TrPs are activated/perpetuated by a chronic rounded shoulder posture, or when driving and holding the top of the steering wheel. Lower trapezius TrPs are activated/perpetuated by chronically pressing the shoulder girdles down (e.g., supporting the chin in the hand, pressing the hands down on the sitting surface when seated).
2. TrPs in the upper trapezius tend to produce a classic stiff neck with restricted contralateral lateral flexion and ipsilateral rotation of the neck at the spinal joints, a posture of an elevated shoulder girdle, pain at the end of contralateral rotation of the neck, and tension headaches. Middle trapezius TrPs tend to produce inhibition and weakness of the middle trapezius resulting in chronically protracted shoulder girdles (rounder shoulders), and goose bumps on the arm (and sometimes on the thigh). Lower trapezius TrPs tend to produce burning pain, and inhibition and weakness of the lower trapezius resulting in elevated shoulders. TrPs in all parts of the trapezius may produce spinal joint dysfunction of the vertebrae to which they are attached.
3. The referral patterns of upper trapezius TrPs must be distinguished from the referral patterns of TrPs in the sternocleidomastoid (SCM), masseter, temporalis, occipitalis, splenius cervicis, levator scapulae, semispinalis capitis, cervical multifidus, and lower trapezius. Middle trapezius referral patterns must be distinguished from the levator scapulae, erector spinae and transversospinalis of the trunk, and lower trapezius. Lower trapezius referral patterns must be distinguished from the cervical multifidus, levator scapulae, rhomboids, scalenes, infraspinatus, latissimus dorsi, serratus anterior, erector spinae and transversospinalis of the trunk, intercostals, and upper trapezius.
4. TrPs in the trapezius are often incorrectly assessed as cervical disc syndrome, temporomandibular joint (TMJ) syndrome, or occipital neuralgia.
5. Associated TrPs of the upper trapezius often occur in the scalenes, splenius capitis and cervicis, levator scapulae, rhomboids, semispinalis capitis, temporalis, masseter, and the contralateral upper trapezius. Associated TrPs of the middle trapezius often occur in the pectoralis major and minor, and the erector spinae and transversospinalis muscles of the trunk. Associated TrPs of the lower trapezius often occur in the latissimus dorsi and ipsilateral upper trapezius.
6. Note: The trapezius is considered to be the muscle most commonly found to have TrPs. Specifically, the upper trapezius has the most commonly found TrP in the body; further, the referral symptoms of this common TrP have occasionally spread to the other side of the body.



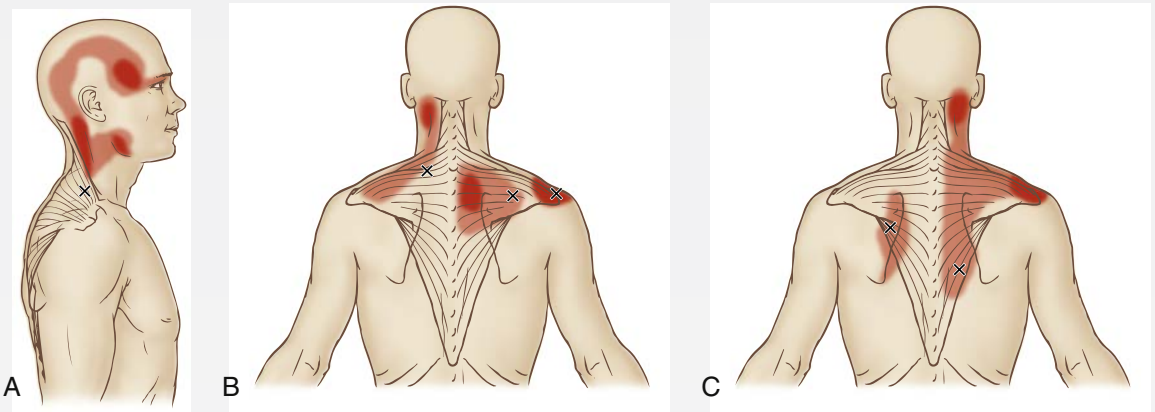


**Figure 10-10** Common trapezius trigger points (TrPs) and their corresponding referral zones. **A** is a lateral view showing the location of a TrP in the most vertical fibers of the upper trapezius. **B** shows another upper trapezius TrP on the left side; the *right side* illustrates middle trapezius TrP locations. **C** shows two lower trapezius TrPs and their referral zones.

## TRAPEZIUS—PRONE—*cont'd*

### STRETCHING THE TRAPEZIUS

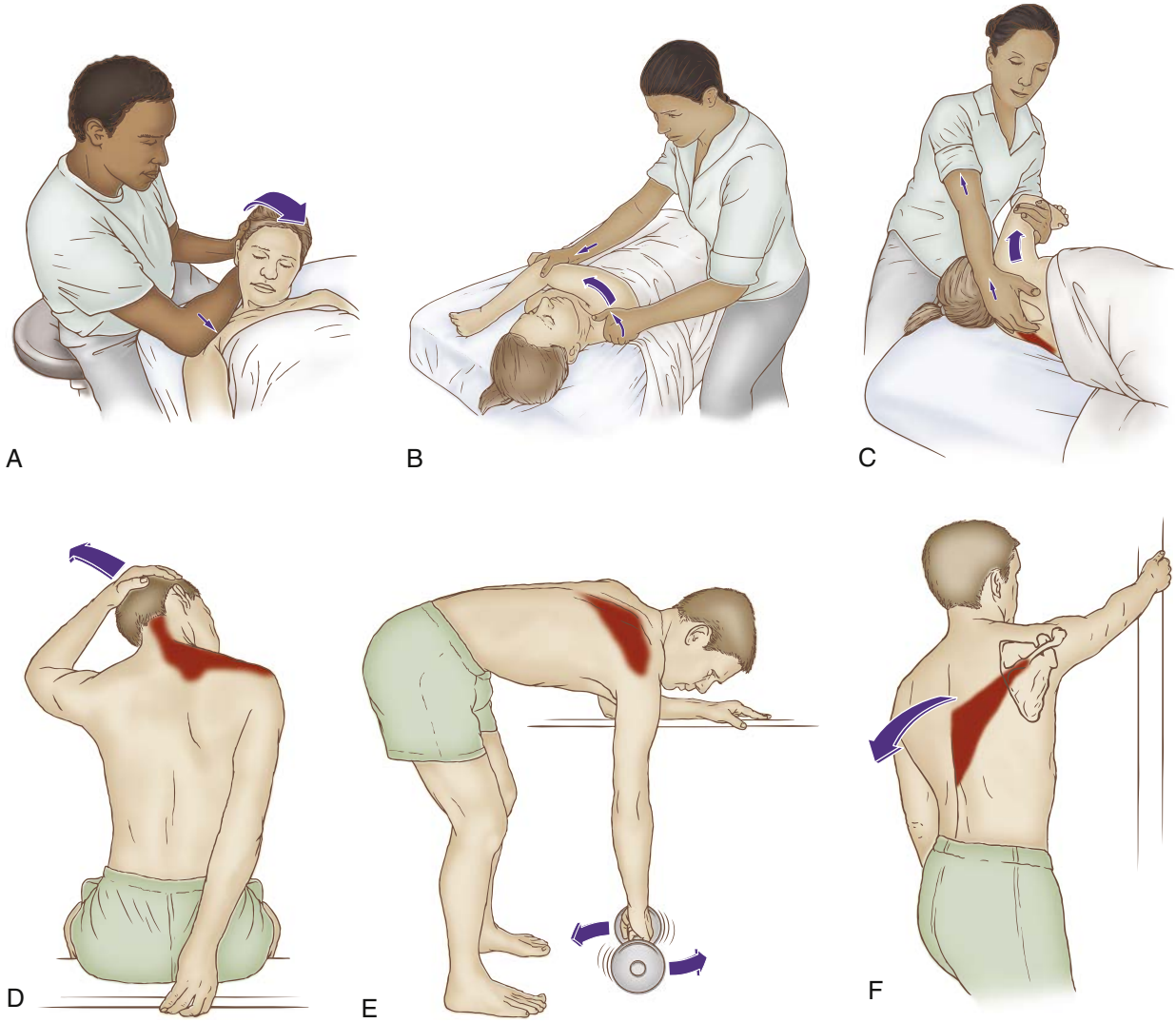


**Figure 10-11** Stretching the three functional parts of the right trapezius. **A, B,** and **C,** Therapist-assisted stretching of the upper, middle, and lower trapezius respectively. **A,** The client's neck is flexed, left laterally flexed, and rotated (ipsilaterally) to the right. Note that the therapist stabilizes the client's shoulder girdle and trunk with the right forearm. **B,** The client's right arm is horizontally flexed to protract the scapula. Note that the therapist assists scapular protraction by curling the fingertips around the medial border of the scapula and pulling. **C,** The client's arm and scapula are moved as in **B,** but are pulled in a more upward direction so that the scapula is protracted and elevated. **D, E,** and **F,** Self-care stretching of the right upper, middle, and lower trapezius respectively. **D,** The client uses the left hand to passively flex, left laterally flex, and right (ipsilaterally) rotate the head and neck. To keep the shoulder girdle down, the right hand holds on to the bench/chair. **E,** A weight is held in the right hand; its traction force protracts the scapula. Medially rotating the right arm enhances the stretch. **F,** A pole is grasped at approximately head height and the client leans back, causing protraction and elevation of the scapula.

## INFRASPINATUS AND TERES MINOR—PRONE—*cont'd*

### STRETCHING THE INFRASPINATUS AND TERES MINOR

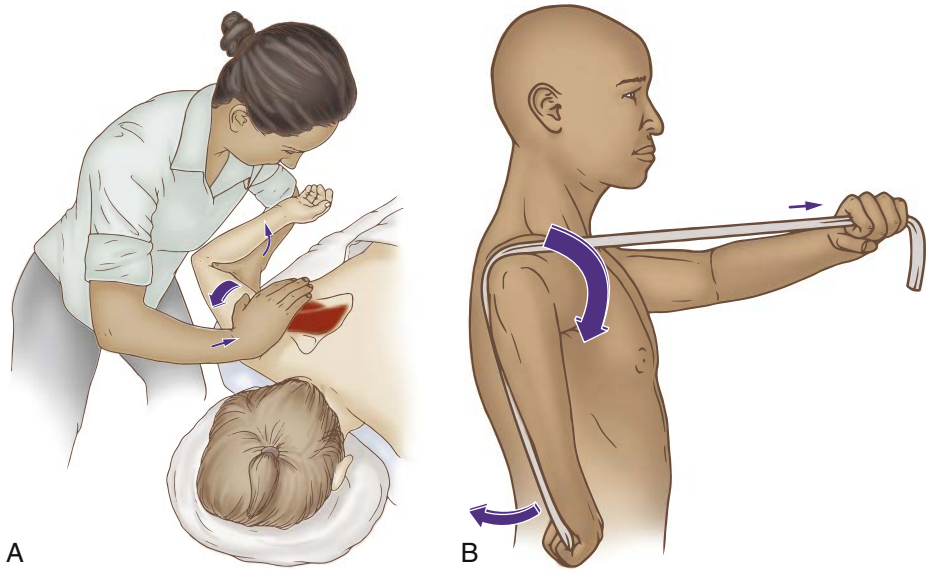


**Figure 10-38** Stretching the right infraspinatus and teres minor. The arm is medially rotated at the glenohumeral (GH) joint. **A,** Therapist-assisted stretch. Note that the client's scapula is stabilized by the therapist's right hand. **B,** Self-care stretch. The client's right arm is medially rotated using a rope.



## TERES MAJOR—PRONE

### ATTACHMENTS

- Inferior angle and inferior ⅓ of the dorsal surface of the lateral border of the scapula

  *to the*

- medial lip of the bicipital groove of the humerus

### ACTIONS

- Medially rotates the arm at the glenohumeral (GH) joint
- Adducts the arm at the GH joint
- Extends the arm at the GH joint
- Upwardly rotates the scapula at the scapulocostal (ScC) and GH joints

### Starting Position (Figure 10-40)

- Client prone with arm abducted 90 degrees to the side and resting on the table, and the forearm hanging off the table
- Therapist seated to the side of the client with the client's forearm between the knees
- Palpating hand placed just lateral to the lower aspect of the lateral border of the scapula

### Palpation Steps

1. Ask the client to medially rotate the arm at the GH joint against the resistance of your knee, and feel for the contraction of the teres major at the inferior aspect of the lateral border of the scapula (Figure 10-41).
2. Continue palpating the teres major distally toward the humerus while strumming perpendicular to its fibers.
3. Once the teres major muscle has been located, have the client relax it and palpate to assess its baseline tone.

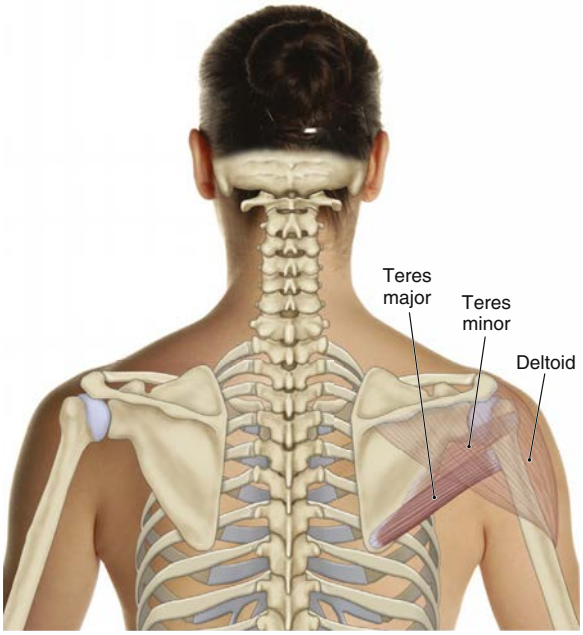


**Figure 10-39** Posterior view of the right teres major. The deltoid and teres minor have been ghosted in.

## TERES MAJOR—PRONE—*cont'd*

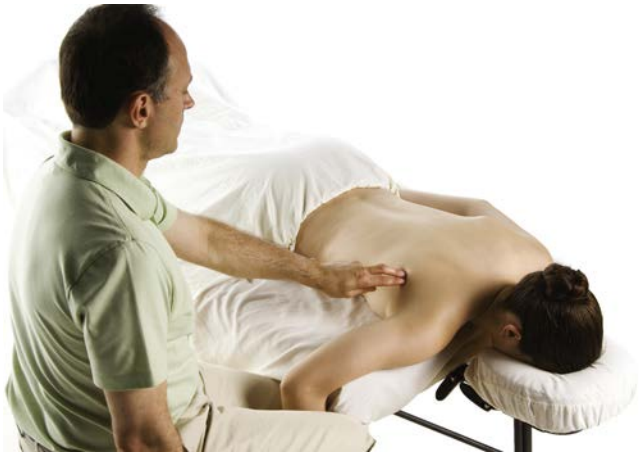

**Figure 10-40** Starting position for prone palpation of the right teres major.

**Figure 10-41** Palpation of the right teres major as the client medially rotates the arm against resistance.



### PALPATION NOTES

1. It is easy to discern the superior border of the teres major from the inferior border of the teres minor. To do so, simply have the client alternate between medial rotation of the arm and lateral rotation of the arm at the glenohumeral (GH) joint (in each case against the resistance of your knee). The teres major contracts with medial rotation, and the teres minor contracts with lateral rotation.
2. It is sometimes challenging to discern the border between the bellies of the teres major and latissimus dorsi. They are located next to each other and they engage with the same actions of the arm at the GH joint. On the humerus, the latissimus dorsi attaches more anteriorly on the humerus than the teres major, but the teres major does attach slightly further distal.

### Alternate Palpation Position—Seated

The teres major can also be easily palpated with the client seated. This palpation should be carried out in a similar manner to the seated palpation of the teres minor and infraspinatus (see Figure 10-36), except that medial rotation of the arm at the GH joint is resisted. If the resistance is given to the forearm (with the elbow joint flexed to 90 degrees), be sure that the client is providing the resistance with medial rotation of the arm at the GH joint and not horizontal flexion of the arm at the GH joint.

**Palpation Key:**
Place client's forearm between your knees; use your knee to provide resistance.

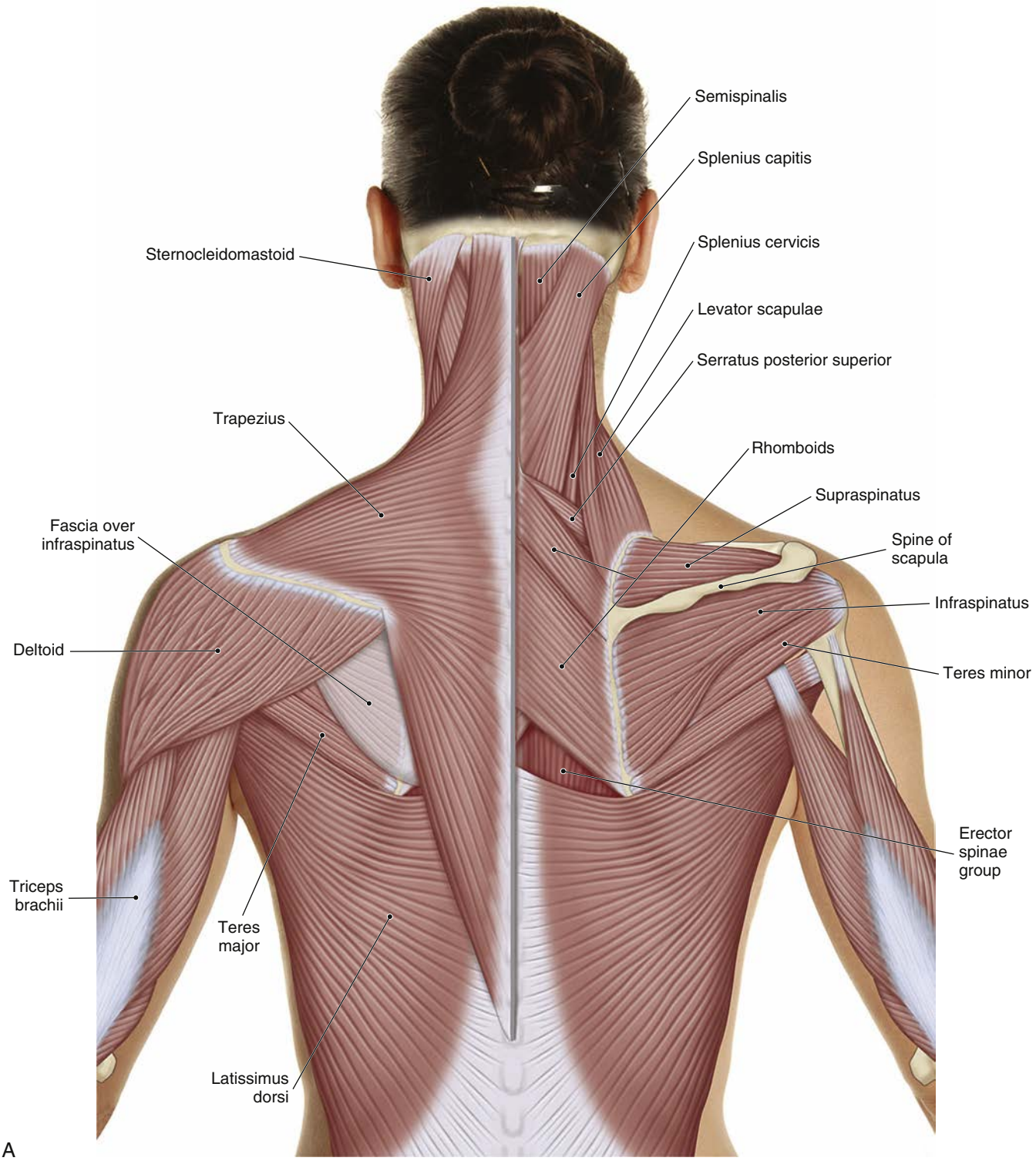


**Figure 11-2** Posterior views of the neck and upper back region. **A,** Superficial views; the trapezius, sternocleidomastoid (SCM), and deltoid have been removed on the right side.

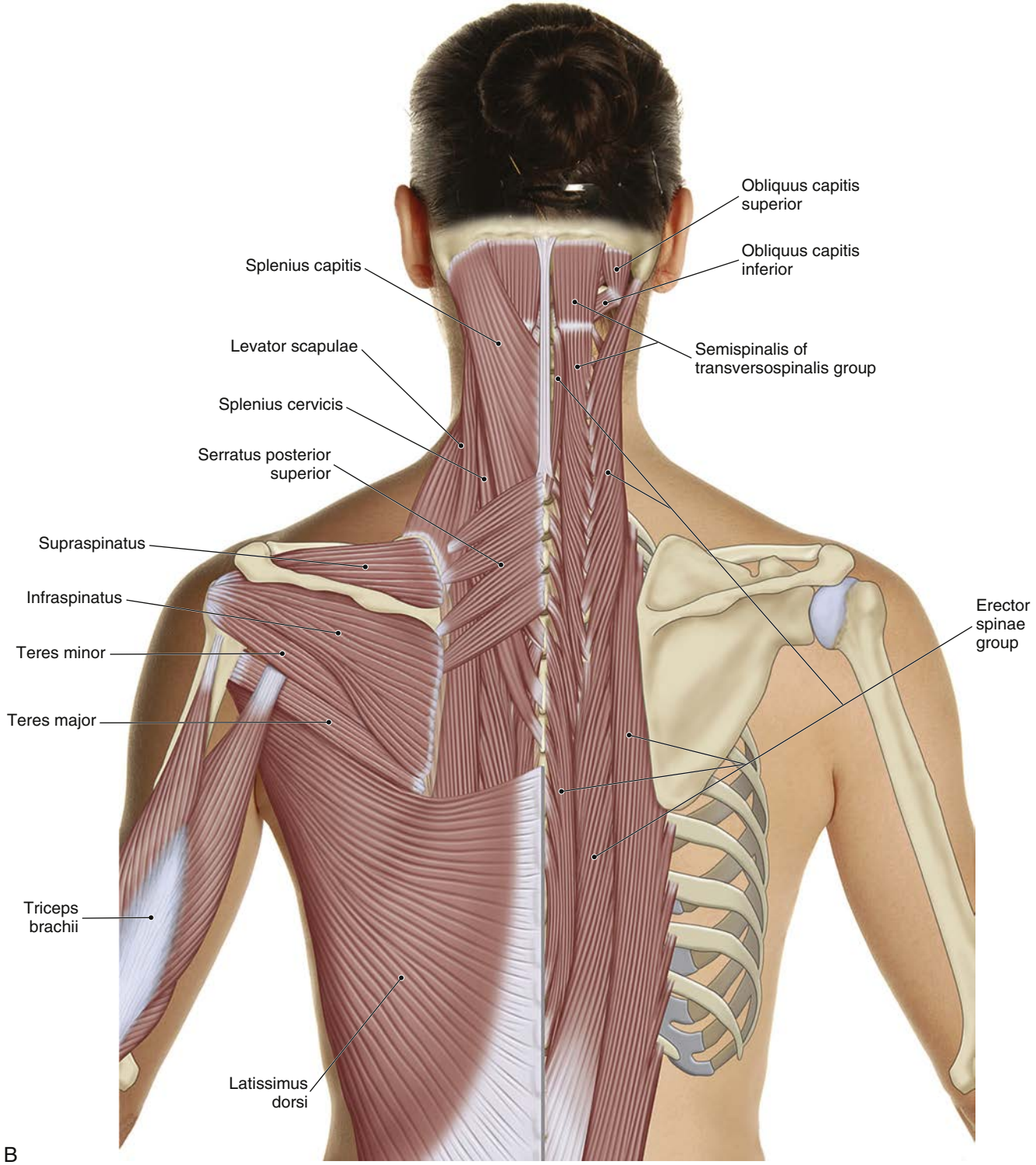


**Figure 11-2, cont'd** **B,** Intermediate views; the serratus posterior superior, splenius capitis and cervicis, levator scapulae, supraspinatus, infraspinatus, teres minor and major, and triceps brachii have been removed on the right side.

## STERNOCLEIDOMASTOID (SCM)—SUPINE

### ATTACHMENTS

- Manubrium of the sternum and the medial ⅓ of the clavicle

*to the*

- mastoid process of the temporal bone and the lateral ½ of the superior nuchal line of the occiput

### ACTIONS

- Flexes the lower neck at the spinal joints
- Extends the head and upper neck at the spinal joints
- Laterally flexes the head and neck at the spinal joints
- Contralaterally rotates the head and neck at the spinal joints
- Elevates the sternum and clavicle

### Starting Position (Figure 11-5)

- Client supine with the head and neck contralaterally rotated
- Therapist seated at the head of the table
- Palpating hand placed just superior to the sternoclavicular joint

### Palpation Steps

1. Ask the client to lift the head and neck from the table, and look for the sternocleidomastoid (SCM) to become visible (Figure 11-6).
2. Although resistance could be added by the support hand, it is often unnecessary because lifting the head and neck against gravity usually provides sufficient resistance.
3. Palpate toward the superior attachment while strumming perpendicular to the fibers.
4. Once the SCM has been located, have the client relax it and palpate to assess its baseline tone.

**Figure 11-5** Starting position for supine palpation of the right sternocleidomastoid (SCM).

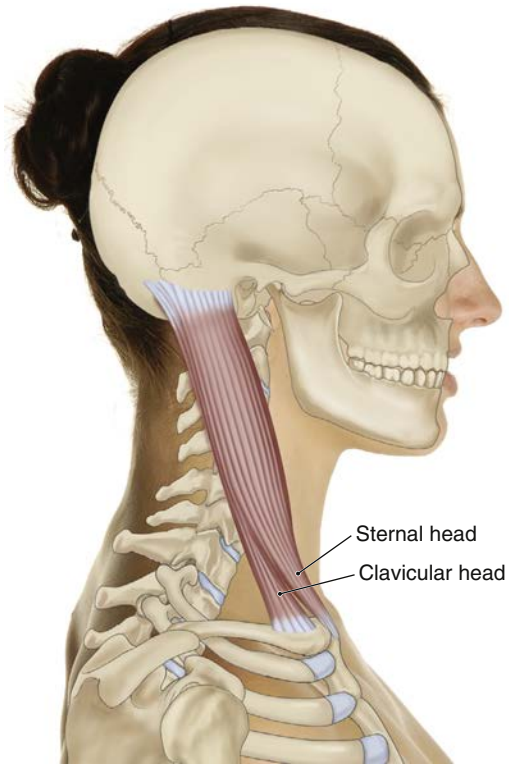


**Figure 11-4** Lateral view of the right sternocleidomastoid (SCM).

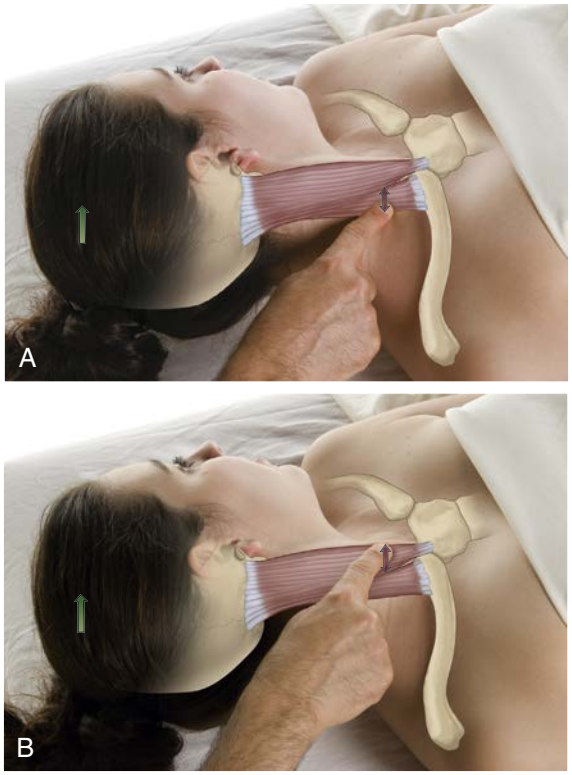


**Figure 11-6** Supine palpation of the right sternocleidomastoid (SCM) as the client raises the head and neck from the table. **A,** Palpation of the clavicular head. **B,** Palpation of the sternal head.

## STERNOCLEIDOMASTOID (SCM)—SUPINE—*cont'd*

### PALPATION NOTES

1. The sternal head of the SCM is usually much more visible than the clavicular head. If the clavicular head is not visible, palpate for it just lateral to the inferior aspect of the sternal head. Note: Although it is common to have a small gap between the sternal and clavicular heads, some people have a large gap and other people have no gap at all.
2. Palpation of the SCM must be done somewhat carefully, because the carotid sinus of the common carotid artery lies deep to the SCM (see Figure 11-1, *B*), and pressure against the carotid sinus can create a reflex that lowers blood pressure. For this reason, pincer palpation is often recommended for palpating the SCM, rather than flat palpation.
3. The SCM forms the anterior border of the posterior triangle of the neck, and is an excellent landmark for locating the scalenes. It also forms the posterior border of the anterior triangle of the neck, and is an excellent landmark for locating the longus colli and longus capitis muscles.



**Palpation Key:**
Turn to the opposite side and lift the head.

### Alternate Palpation Position—Seated

**Figure 11-7** The sternocleidomastoid (SCM) can be easily palpated with the client seated. Ask the client to rotate the head and neck to the opposite side (contralaterally rotate) and slightly laterally flex to the same side; then resist any further lateral flexion to the same side. The sternal head often becomes visible with contralateral rotation. Resistance to same side lateral flexion usually brings out the clavicular head (indicated). If the clavicular head is not visible, try increasing the resistance to lateral flexion.

### TRIGGER POINTS

1. Trigger points (TrPs) in the sternocleidomastoid (SCM) often result from or are perpetuated by acute or chronic overuse of the muscle (e.g., chronic postures of sitting with the head turned to one side or looking upward to paint a ceiling, a chronic cough using the muscle for its respiratory function), chronic postures that result in shortening of the muscle (e.g., having a protracted head posture, looking downward to read a book in the lap by flexing the lower cervical spine, sleeping with a pillow that is too thick), irritation from wearing a tie or a shirt with a tight collar, or trauma (e.g., whiplash, fall).
2. TrPs in the SCM tend to produce headaches, altered posture of ipsilateral lateral flexion of the head and neck, restricted range of motion of the neck and head, a sore throat, autonomic nervous system symptoms (sternal head: eye symptoms, such as ptosis of the upper eyelid, loss of visual acuity, and excessive tear formation; clavicular head: localized vasoconstriction and increased sweating), proprioceptive symptoms (sternal head: dizziness, vertigo, nausea, and ataxia; clavicular head: hearing loss), and even entrapment of cranial nerve XI (spinal accessory nerve).
3. The referral patterns of SCM TrPs must be distinguished from the referral patterns of TrPs in the trapezius, semispinalis capitis, suboccipitals, temporalis, masseter, digastric (due to pain referral and possible throat symptoms), lateral and medial pterygoids, occipitofrontalis, platysma, longus colli and capitis (due to possible throat symptoms), and some muscles of facial expression.
4. TrPs in the SCM are often incorrectly assessed as swollen lymph nodes, sinus or migraine headaches, osteoarthritis of the sternoclavicular joint, trigeminal neuralgia, tic douloureux, or neurogenic spasmodic torticollis.
5. Associated TrPs often occur in the scalenes, platysma, levator scapulae, trapezius, splenius capitis and cervicis, semispinalis capitis, temporalis, masseter, digastric, and contralateral SCM.
6. The referral pain of SCM TrPs can cross over to the other side of the body.

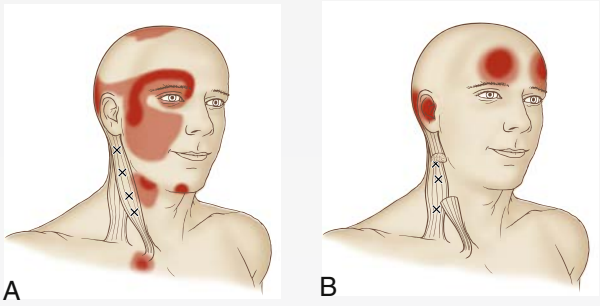


**Figure 11-8** Anterolateral views illustrating common sternocleidomastoid (SCM) trigger points (TrPs) and their corresponding referral zones. **A,** Sternal head. **B,** Clavicular head.

## STERNOCLEIDOMASTOID (SCM)—SUPINE—*cont'd*

### STRETCHING THE STERNOCLEIDOMASTOID

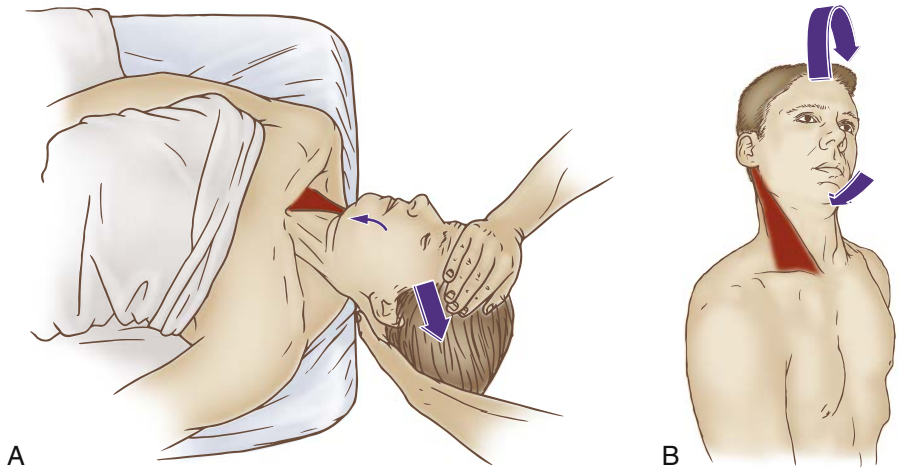


**Figure 11-9** Stretching the right sternocleidomastoid (SCM). The client's head and neck are left laterally flexed and rotated to the right, and the lower neck is extended but the chin is tucked (to flex the head). **A,** Therapist-assisted stretch. Note: Caution is advised whenever bringing the client's head down into extension. **B,** Self-care stretch.



### DETOUR

**Platysma:**
The platysma is a very thin superficial sheet of muscle that attaches from the subcutaneous fascia of the superior chest to the mandible and subcutaneous fascia of the lower face (Figure 11-10, *A*). When it contracts, it creates wrinkles in the skin of the neck. It can be engaged by asking the client to forcefully depress and draw the lower lip laterally while keeping the mandible in a position of slight depression (see Figure 11-10, *B*).

**Trigger Points**

1. Trigger points (TrPs) in the platysma (Figure 11-10, *C*) often result from or are perpetuated by acute or chronic overuse of the muscle (e.g., habitual expression of disgust or horror) and TrPs in the SCM and scalene muscles.
2. TrPs in the platysma tend to produce prickly pain over the mandible.
3. The referral patterns of platysma TrPs must be distinguished from the referral patterns of TrPs in the SCM, masseter, temporalis, and medial pterygoid.
4. TrPs in the platysma are often incorrectly assessed as temporomandibular joint (TMJ) dysfunction.
5. Associated TrPs often occur in other muscles of facial expression.
6. Note: TrPs in the platysma are usually located over the SCM.

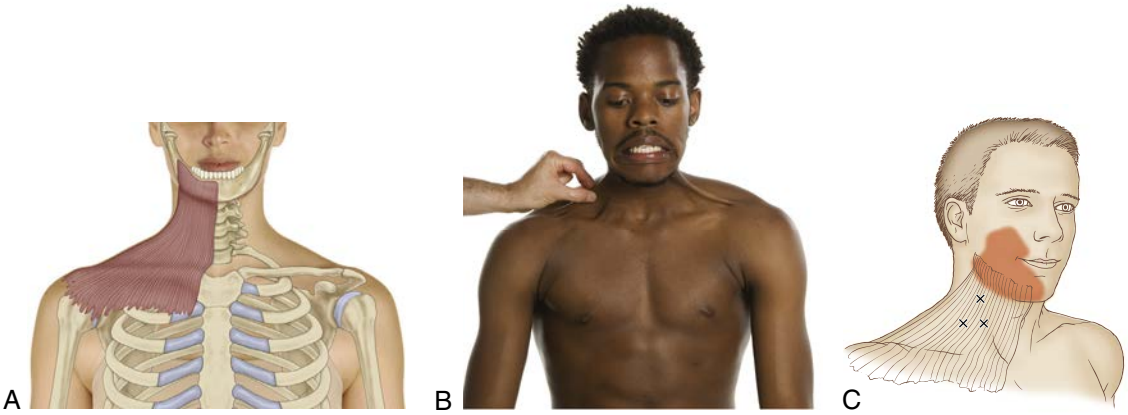


**Figure 11-10** Views of the platysma. **A,** Anterior view of the right platysma. **B,** Anterior view of the platysma contracted and being palpated. **C,** Anterolateral view illustrating common platysma trigger points (TrPs) and their corresponding referral zone.

## BRACHIORADIALIS—SEATED—*cont'd*

### PALPATION NOTES

1. The brachioradialis is superficial for its entire path except where the abductor pollicis longus and extensor pollicis brevis cross superficial to it in the distal forearm.
2. The three major flexors of the elbow joint are the biceps brachii, the brachialis, and the brachioradialis. They are all palpated by resisting flexion of the forearm at the elbow joint; the difference is the position of the forearm. For palpation of the biceps brachii, the forearm is fully supinated; for the brachialis, the forearm is fully pronated; for the brachioradialis, the forearm is halfway between full pronation and full supination (Figure 14-7).
3. The "key" to recall the palpation position for the brachioradialis is to think of the position of the upper extremity when hitchhiking: the forearm is flexed and halfway between full pronation and full supination. However, the thumb should be relaxed; if it is extended as in hitchhiking, the abductor pollicis longus and extensor pollicis brevis will contract, making it more difficult to palpate the distal end of the brachioradialis.




**Figure 14-7** Palpation of the three major elbow joint flexors as forearm flexion at the elbow joint is resisted. Note that the difference between the three palpations lies in the degree of pronation or supination of the forearm at the radioulnar joints. **A,** Palpation of the biceps brachii with the forearm fully supinated. **B,** Palpation of the brachialis with the forearm fully pronated. **C,** Palpation of the brachioradialis with the forearm halfway between full supination and full pronation.

## LATISSIMUS DORSI—PRONE—*cont'd*

### Alternate Palpation Position—Standing

The latissimus dorsi can be easily palpated with the client standing. The client stands with the arm on the shoulder of the therapist, who is standing to the front and side of the client. Ask the client to push his arm down onto your shoulder in the direction of extension and adduction of the arm at the GH joint, and feel for the contraction of the latissimus dorsi. In this position, it is especially easy to follow the latissimus dorsi to its humeral attachment.


**Figure 16-8** Standing palpation of the right latissimus dorsi. **A,** The starting position in which the client has his distal arm (just proximal to the elbow joint) on the shoulder of the therapist. **B,** Shows palpation of the humeral attachment as the client tries to move the arm obliquely toward extension and adduction against resistance.

## QUADRATUS LUMBORUM (QL)——PRONE—*cont'd*

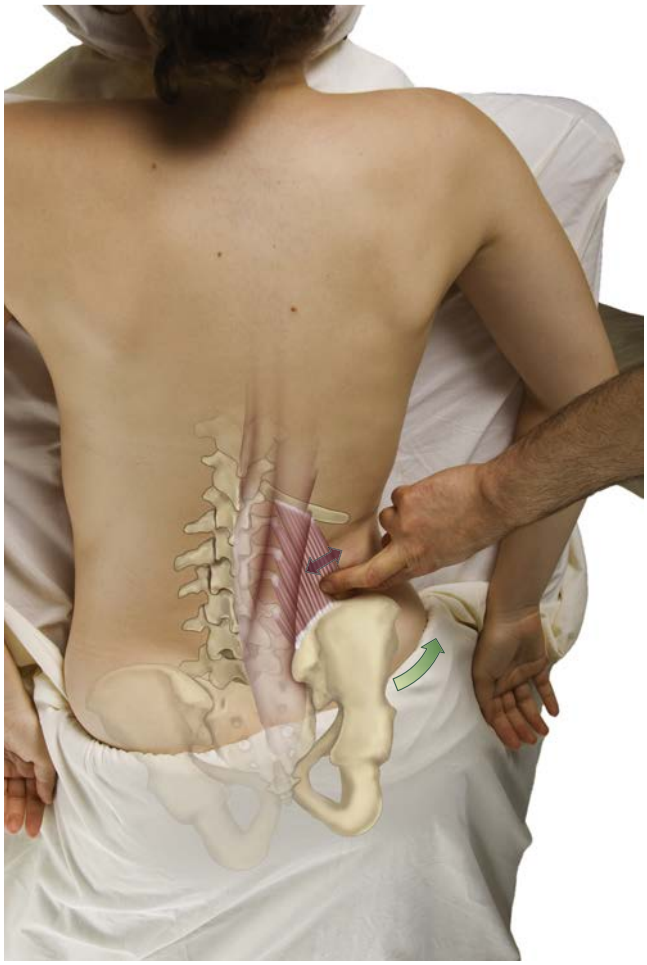

**Figure 16-27** Palpation of the right quadratus lumborum (QL) as the client elevates the right side of the pelvis. The outline of the right erector spinae group has been ghosted in.

**Figure 16-28** Once the quadratus lumborum (QL) has been located, palpate in all three directions toward the rib, transverse process, and iliac attachments.

### PALPATION NOTES

1. The QL cannot be palpated through the erector spinae musculature because the erector spinae is so thick. To successfully palpate the QL, you must be lateral to the erector spinae, and then press in firmly with a medial direction to your pressure.
2. The client in Figure 16-28 has a lot of the QL accessible lateral to the erector spinae musculature. However, the amount of exposure of the QL lateral to the erector spinae varies. In some individuals, the erector spinae is wider and/or the QL is narrower, causing very little of the QL to be accessible lateral to the erector spinae musculature.
3. Whenever pressing deeply to palpate a muscle, always press in firmly but slowly! Ask the client to take in a deep breath, and then slowly press in as the client exhales. This procedure may be repeated two to three times, each time pressing in slightly deeper to access the QL.
4. The rib and iliac crest attachments of the QL are usually the easiest to palpate; the transverse processes attachment is usually the most challenging to palpate.

### Alternate Palpation Position—Side Lying

**Figure 16-29** The quadratus lumborum (QL) can be easily palpated with the client side lying. As with the prone palpation, be sure that your palpating fingers are first located lateral to the erector spinae musculature. In this position, press down toward the table to access the belly and attachments of the QL.

# EXTERNAL AND INTERNAL ABDOMINAL OBLIQUES—SUPINE

## External Abdominal Oblique

### ATTACHMENTS

- Abdominal aponeurosis, pubic bone, inguinal ligament, and the anterior iliac crest

  *to the*

- lower eight ribs (Figure 16-51, *A*)

### ACTIONS

- Flexes the trunk at the spinal joints
- Laterally flexes the trunk at the spinal joints
- Contralaterally rotates the trunk at the spinal joints
- Posteriorly tilts the pelvis at the lumbosacral (LS) joint
- Elevates the pelvis at the LS joint
- Ipsilaterally rotates the pelvis at the LS joint
- Compresses the abdominal contents

## Internal Abdominal Oblique

### ATTACHMENTS

- Inguinal ligament, iliac crest, and thoracolumbar fascia

  *to the*

- lower three ribs and abdominal aponeurosis (see Figure 16-51, *B*)

### ACTIONS

- Flexes the trunk at the spinal joints
- Laterally flexes the trunk at the spinal joints
- Ipsilaterally rotates the trunk at the spinal joints
- Posteriorly tilts the pelvis at the LS joint
- Elevates the pelvis at the LS joint
- Contralaterally rotates the pelvis at the LS joint
- Compresses the abdominal contents

### Starting Position (Figure 16-52)

- Client supine with a small roll under the knees
- Therapist standing to the side of the client
- Palpating hand placed on the anterolateral abdominal wall

### Palpation Steps

1. With palpating hand on the anterolateral abdominal wall between the iliac crest and the lower ribs (Be sure that you are lateral to the rectus abdominis.), ask the client to rotate the trunk to the opposite side of the body (contralateral rotation) and feel for the contraction of the external abdominal oblique (Figure 16-53, *A*).
2. Try to feel for the diagonal orientation of the external abdominal oblique fibers by strumming perpendicular to them.
3. Continue palpating the external abdominal oblique toward its superior and inferior attachments.
4. Repeat the same procedure for the internal abdominal oblique, asking the client to instead flex and ipsilaterally rotate the trunk at the spinal joints (see Figure 16-53, *B*).
5. Once the external abdominal and internal abdominal obliques have been located, have the client relax them, and palpate to assess their baseline tone.


**Figure 16-51** The right abdominal obliques. **A,** Lateral view of the right external abdominal oblique. **B,** Lateral view of the right internal abdominal oblique.

**Figure 16-52** Starting position for supine palpation of the right external and internal abdominal obliques.

## PIRIFORMIS—PRONE

### ATTACHMENTS

- Anterior surface of the sacrum

  *to the*

- greater trochanter of the femur

### ACTIONS

- Laterally rotates the thigh at the hip joint
- If the thigh is first flexed approximately 60 degrees or more, the piriformis becomes a medial rotator of the thigh at the hip joint
- If the thigh is first flexed to 90 degrees, the piriformis horizontally abducts the thigh at the hip joint

### Starting Position (Figure 17-21)

- Client prone with the leg flexed to 90 degrees at the knee joint
- Therapist standing to the side of the client
- Palpating hand placed just lateral to the sacrum, halfway between the posterior superior iliac spine (PSIS) and the apex of the sacrum
- Support hand placed on the medial surface of the distal leg, just proximal to the ankle joint

### Palpation Steps

1. Begin by finding the point on the lateral sacrum that is halfway between the PSIS and the apex of the sacrum. Drop just off the sacrum laterally at this point, and you will be on the piriformis.
2. Resist the client from laterally rotating the thigh at the hip joint, and feel for the contraction of the piriformis (Figure 17-22). Note: Lateral rotation of the client's thigh involves the client's foot moving medially toward the midline (and opposite side) of the body.
3. Continue palpating the piriformis laterally toward the superior border of the greater trochanter of the femur while strumming perpendicular to the fibers as the client alternately contracts (against resistance) and relaxes the piriformis.
4. Once the piriformis has been located, have the client relax it, and palpate to assess its baseline tone.

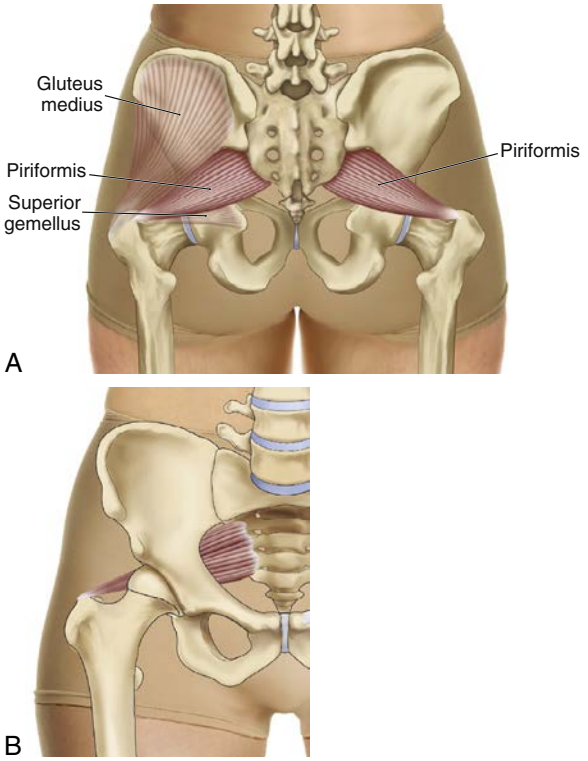


**Figure 17-20** Views of the piriformis. **A,** Posterior view. The piriformis has been drawn on both sides. The gluteus medius and superior gemellus have been ghosted in on the left. **B,** Anterior view of the right piriformis, showing its attachment onto the anterior surface of the sacrum.

**Figure 17-21** Starting position for prone palpation of the right piriformis.

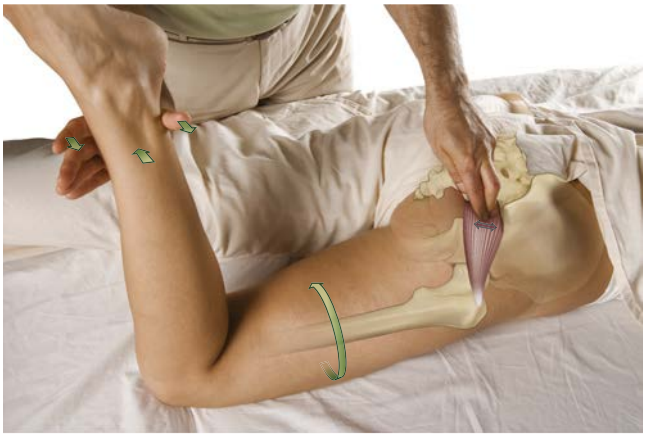

**Figure 17-22** Palpation of the right piriformis as the client attempts to laterally rotate the thigh at the hip joint against gentle to moderate resistance.

## QUADRICEPS FEMORIS GROUP—SUPINE—*cont'd*

### STRETCHING THE QUADRICEPS FEMORIS

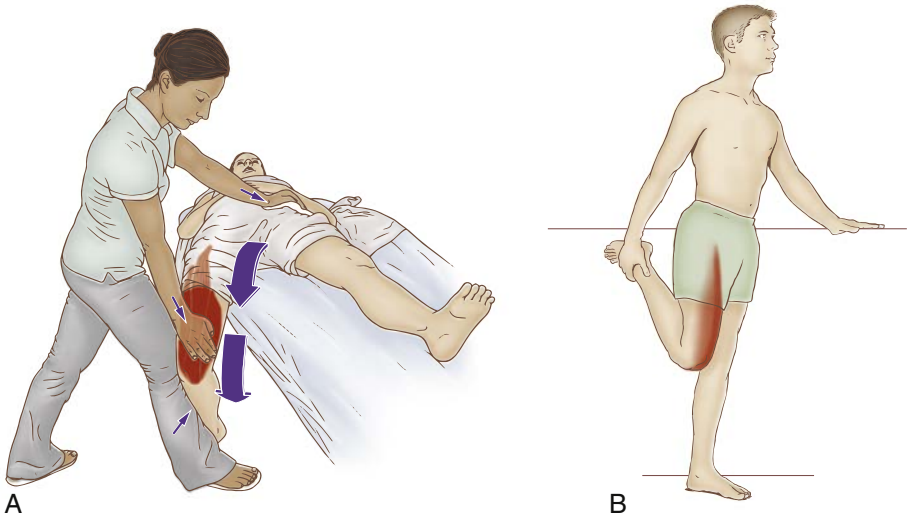


**Figure 18-33** Stretching the right quadriceps femoris group. The client's knee joint is brought into flexion. If the hip joint is extended, the stretch is focused on the rectus femoris of the quadriceps. **A,** Therapist-assisted stretch. The therapist extends the client's hip joint by contacting the client's distal anterior thigh with her right hand and flexes the client's knee joint by contacting the client's anterior leg with her right leg. Note: The therapist's other hand stabilizes the client's pelvis from anteriorly tilted and rotating to the side of the stretch; a cushion is used for comfort. **B,** Self-care stretch. Note: It is important when doing this stretch to make sure that the knee joint is not rotated.

## PECTINEUS—SUPINE

### ATTACHMENTS

- Superior pubic ramus

*to the*

- pectineal line on the proximal posterior shaft of the femur

### ACTIONS

- Adducts the thigh at the hip joint
- Flexes the thigh at the hip joint
- Anteriorly tilts the pelvis at the hip joint

### Starting Position (Figure 18-35, *A*)

- Client supine with the right thigh on the table and right leg hanging off the table
- Therapist standing to the side of the client
- Place palpating fingers on the proximal anteromedial thigh, and locate the proximal tendon of the adductor longus. To locate it, simply palpate along the pubic bone from lateral to medial until you encounter a prominent tendon (It is the most prominent tendon in the region.) (see Figure 18-35, *B*)
- Support hand placed on the distal anteromedial thigh, just proximal to the knee joint

### Palpation Steps

1. After locating the proximal tendon of the adductor longus, drop off it anteriorly (laterally), and you will be on the pectineus (see Figure 18-35, *C*).
2. To engage the pectineus, palpate against the pubic bone while asking the client to adduct the thigh at the hip joint. Using your support hand to add resistance is usually helpful (Figure 18-36).
3. Once located, strum perpendicular to the fibers and continue palpating the pectineus distally as far as possible.
4. Once the pectineus has been located, have the client relax it, and palpate to assess its baseline tone.

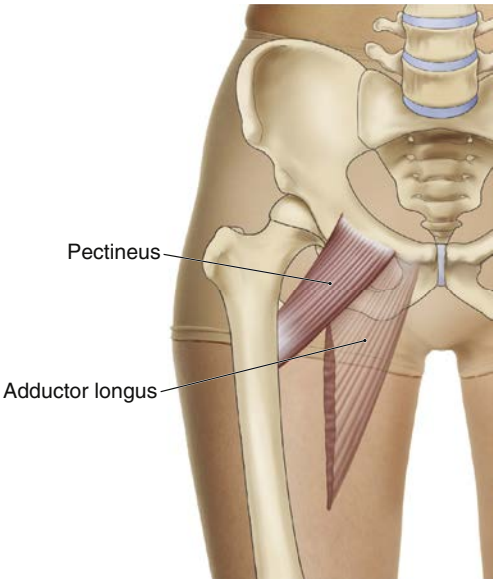


**Figure 18-34** Anterior view of the right pectineus. The adductor longus has been cut and ghosted in.

## PECTINEUS—SUPINE—*cont'd*

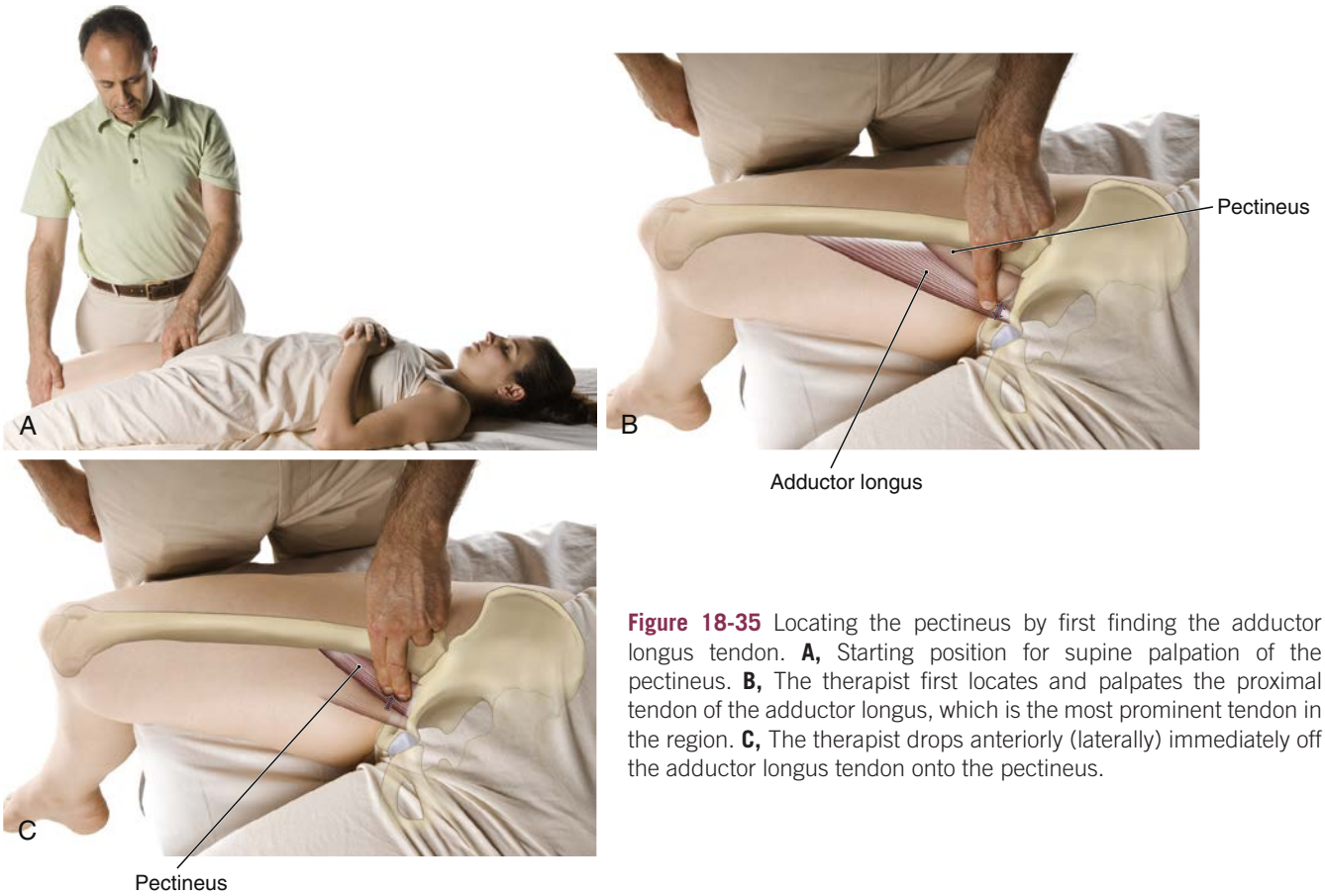


**Figure 18-35** Locating the pectineus by first finding the adductor longus tendon. **A,** Starting position for supine palpation of the pectineus. **B,** The therapist first locates and palpates the proximal tendon of the adductor longus, which is the most prominent tendon in the region. **C,** The therapist drops anteriorly (laterally) immediately off the adductor longus tendon onto the pectineus.

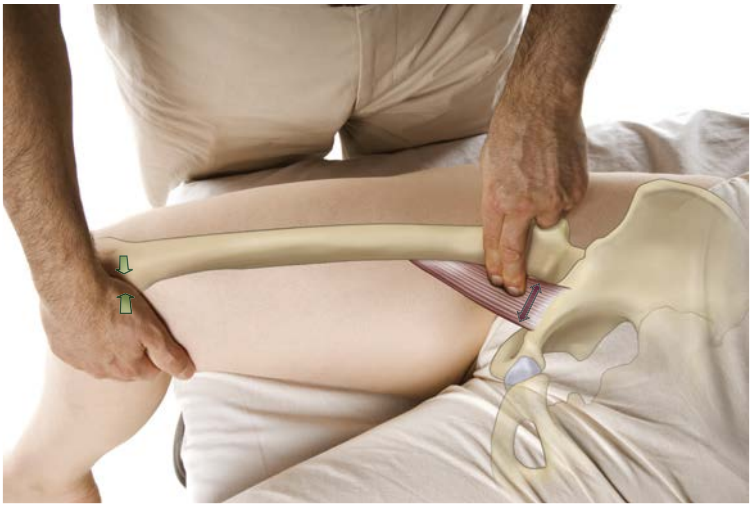

**Figure 18-36** This figure shows engagement and palpation of the pectineus as the client adducts the thigh against resistance.

## PECTINEUS—SUPINE—*cont'd*

### PALPATION NOTES

1. When locating the pectineus, the adductor longus tendon is an excellent landmark to use because it is the most prominent tendon in this region of the thigh. When locating it, it is necessary to palpate directly next to the pubic bone. If you are too far distal in the thigh, you will not be able to feel it.
2. Another way to find the pectineus is to first locate the distal tendon of the iliopsoas and then drop off it medially (posteriorly), and you will be on the pectineus. The border between the iliopsoas and pectineus can be distinguished by asking the client to perform a gentle to moderate curl-up of the trunk. This will tense the psoas major tendon but not the pectineus. If you are still on the iliopsoas, keep moving medially along the pubic bone; once you reach tissue that does not engage and tense with this trunk motion, you are on the pectineus.
3. Even though much of the pectineus is superficial, it is recessed compared with the adjacent muscles. When palpating for the pectineus, it often feels as though the palpating fingers drop into a depression or pocket. For this reason, it is sometimes slightly difficult to locate at first and may require either deeper pressure or greater resistance to adduction of the thigh at the hip joint.
4. Keep in mind that asking the client to actively adduct the thigh at the hip joint will cause the other adductors in the region to contract as well.
5. If asking the client to adduct the thigh at the hip joint does not engage the pectineus, you can try asking the client to flex the thigh instead, or to move in an oblique plane motion that combines flexion with adduction of the thigh. (Resistance can be added with your support hand.) However, keep in mind that all muscles in the anterior thigh will contract with thigh flexion.
6. Be careful when palpating the proximal anterior thigh, because the femoral nerve, artery, and vein are located over the iliopsoas and pectineus in this region. If you feel a pulse under your fingers, either gently move the artery out of the way or slightly move your palpating fingers off the artery. Similarly, if you are pressing on the femoral nerve and the client feels shooting pain, move your palpating fingers off the nerve.

### TRIGGER POINTS

1. Trigger points (TrPs) in the pectineus often result from or are perpetuated by acute or chronic overuse of the muscle (during activities such as horseback riding, gymnastics, or sexual intercourse), or prolonged shortening of the muscle due to sitting cross-legged or sleeping in the fetal position. They may also occur secondary to degenerative joint disease of the hip.
2. TrPs in the pectineus tend to produce deep dull pain in the groin.
3. The referral patterns of pectineus TrPs must be distinguished from the referral patterns of TrPs in the iliopsoas, sartorius, gracilis, and the three "adductors" of the thigh.
4. TrPs in the pectineus are often incorrectly assessed as degenerative joint disease of the hip or obturator nerve entrapment.
5. Associated TrPs often occur in the iliopsoas, gracilis, and the three "adductors" of the thigh.

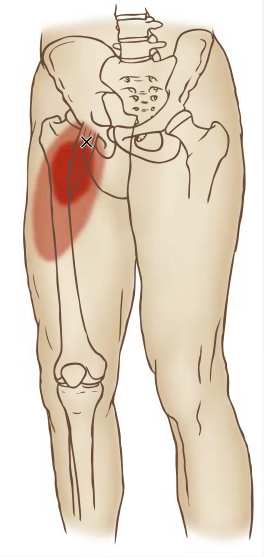

**Figure 18-37** Anteromedial view showing a common pectineus trigger point (TrP) with its corresponding referral zone.



**Palpation Key:**
Drop anteriorly off the adductor longus tendon.

## PECTINEUS—SUPINE—*cont'd*

### STRETCHING THE PECTINEUS

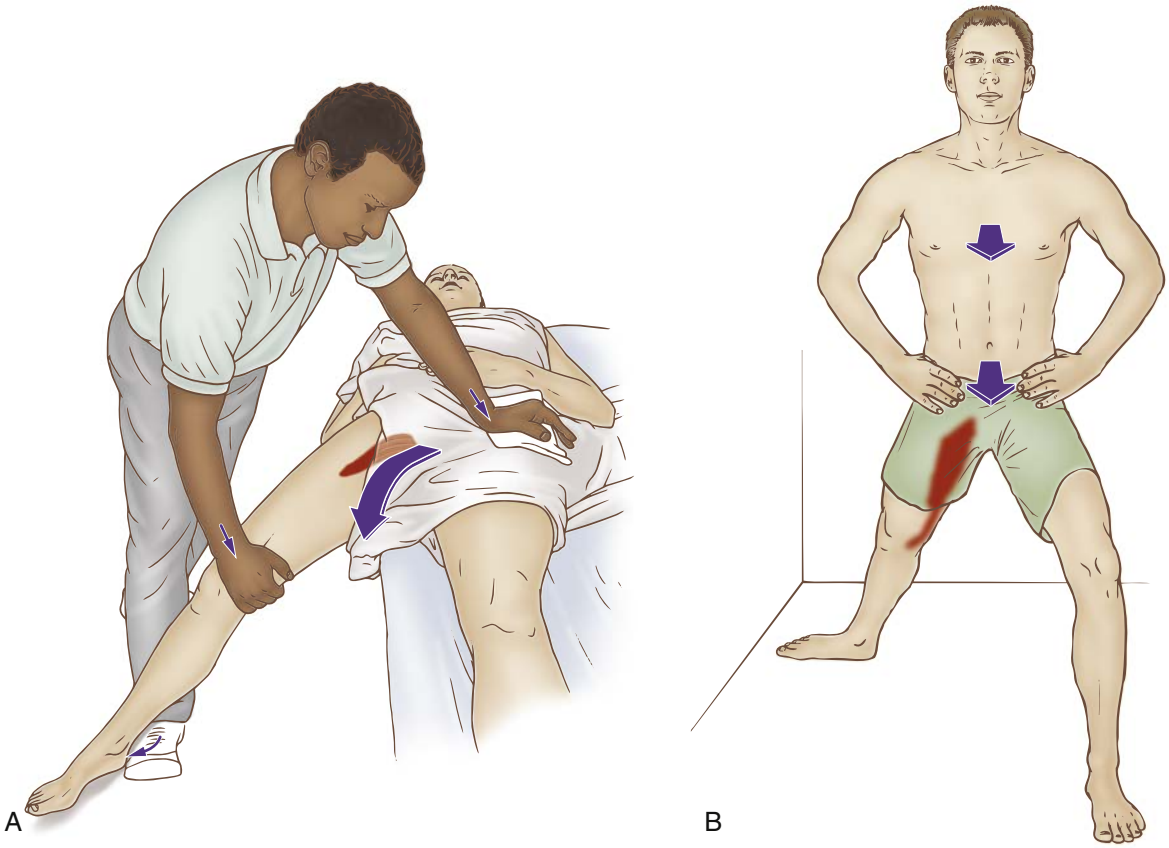


**Figure 18-38** Stretching the right pectineus. The client's thigh is abducted, extended, and laterally rotated with the knee joint in full extension. **A,** Therapist-assisted stretch. The therapist moves the client's thigh with his right hand and maintains extension of the client's knee joint with his right foot and leg. Note: The therapist's other hand stabilizes the client's pelvis from anteriorly tilted and rotating to the side of the stretch; a cushion is used for comfort. **B,** Self-care stretch. Note: It is important to make sure that excessive weight is not placed on the ankle joint of the foot in back. See Figure 18-43 and Figure 18-57 for two other stretches of the pectineus.

WHIRLWIND TOUR

## Muscles of the Thigh

The following *Whirlwind Tour* is an abbreviated set of palpation protocols for the muscles of this chapter. Once you have read and become comfortable with each of the protocols presented thus far, this *Whirlwind Tour* allows you to quickly and efficiently run through the palpations protocols for all the muscles of the chapter.

For all palpations of the muscles of the thigh, the therapist is standing to the side of the client.

### Client Supine

For all palpations of the muscles of the thigh except the prone palpation of the hamstrings at the end, the client is supine with the right thigh on the table and right leg hanging off the table.

1. **Tensor fasciae latae (TFL):** Have the client first medially rotate the thigh at the hip joint and then flex the thigh into the air. Palpating just distal and lateral to the anterior superior iliac spine (ASIS), feel for the contraction of the TFL. Strum perpendicular, and palpate to the distal attachment.
2. **Sartorius:** Have the client first laterally rotate the thigh at the hip joint and then flex the thigh into the air. Palpating just distal and medial to the ASIS, feel for the contraction of the sartorius. Strum perpendicular, and palpate toward the distal attachment as far as possible. Distally, the sartorius is directly posterior to the vastus medialis; use extension of the leg at the knee joint to locate the vastus medialis. Confirm that you are on the distal sartorius by asking the client to flex the leg at the knee joint against the resistance of the table.
3. **Quadriceps femoris group:** Proximally, the rectus femoris is between the sartorius and the TFL. Find either one of these muscles and then drop onto the rectus femoris. Ask the client to extend the leg at the knee joint, and feel for the contraction of the rectus femoris. Strum perpendicular, and palpate to the distal attachment. Palpate in the distal anteromedial thigh for the vastus medialis and in the anterolateral, lateral, and posterolateral thigh for the vastus lateralis, always using leg extension to engage these muscles.
4. **Iliopsoas distal belly and tendon:** Find the proximal attachment of the sartorius and drop immediately medial onto the distal belly and tendon of the iliopsoas. Ask the client to do a gentle to moderate curl-up of the trunk and feel for the tensing of the belly and tendon of the psoas major. Be aware of the presence of the femoral nerve, artery, and vein in this region.
5. **Adductor longus:** Palpate along the pubic bone within the anteromedial thigh, feeling for the prominent tendon of the adductor longus. Once located, ask the client to adduct the thigh against gentle to moderate resistance, and feel for the contraction of the adductor longus. Strum perpendicular, and continue palpating distally as far as possible. Be aware that all adductors in this region will contract with resisted adduction of the thigh.
6. **Pectineus:** First locate the proximal tendon of the adductor longus, and then drop immediately off it laterally (anteriorly) onto the pectineus. Ask the client to adduct and/or flex the thigh at the hip joint, and feel for its contraction. Pressing deeper and/or adding greater resistance may be necessary. Strum perpendicular, and continue palpating the pectineus distally as far as possible. Be aware of the presence of the femoral nerve, artery, and vein in this region.
7. **Gracilis:** First find the proximal tendon of the adductor longus, and then drop off it immediately medially (posteriorly) onto the gracilis. Ask the client to flex the leg at the knee joint by pressing the leg against the table, and feel for the contraction of the gracilis. Strum perpendicular to the fibers and follow distally to the pes anserine. Note: The distal tendon can also be located by palpating the distal posteromedial thigh and asking the client to medially rotate the leg at the knee joint, feeling for the gracilis and semitendinosus tendons to noticeably tense. The gracilis is the smaller and more medially located of the two tendons. Strum perpendicular, and palpate it proximally to the pubic bone.
8. **Adductor magnus:** Palpate immediately posterior from the gracilis onto the adductor magnus. You know you are on the adductor magnus when you do not feel a contraction when the client presses the leg against the table (flexion of the leg at the knee joint). Confirm you are on the adductor magnus by resisting the client from adducting the thigh at the hip joint (Be aware that all adductors in this region may engage with this action.) or by extending the thigh at the hip joint by pressing the thigh against the table. (Be aware that the hamstrings will likely engage with this action.) Palpate distally as far as possible while strumming perpendicular to the fibers. Note: The adductor magnus is located between the gracilis and medial hamstring musculature; these muscles can be felt to contract when the client presses the leg against the table (flexion of the leg at the knee joint). The adductor magnus does not cross the knee joint and stays relaxed when the leg flexes at the knee joint.
9. **Hamstrings (supine):** From the adductor magnus, palpate immediately posterior onto the medial hamstrings (semitendinosus and semimembranosus). Confirm that you are on the hamstrings by feeling their contraction when the client presses the leg against the table (flexion of the leg at the knee joint).

### Client Prone with the Leg Partially Flexed at the Knee Joint

10. **Entire hamstring group:** Resist the client from further flexing the leg at the knee joint, and feel for the common proximal attachment of the hamstring group just distal to the ischial tuberosity. Strum perpendicular to the fibers, and continue palpating the biceps femoris distally toward the head of the fibula. Then strum perpendicularly and continue palpating the medial hamstrings distally toward the medial side of the leg. The medial and lateral hamstrings are side by side in the proximal thigh, but they diverge in the distal thigh. Note: The semitendinosus is generally superficial to the semimembranosus, and its distal tendon is very prominent. Palpate on either side of the distal semitendinosus for the semimembranosus.